

Macular Degeneration and Integrative Manual Therapy

Kimberly Burnham, PhD, IMTC, LMT
Integrative Manual Therapy Certified
Matrix Energetics Certified

2009

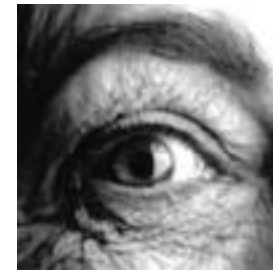
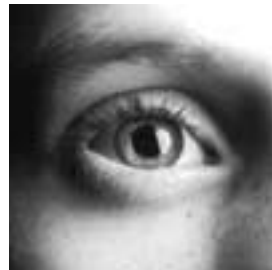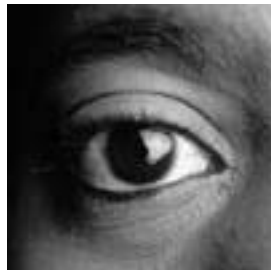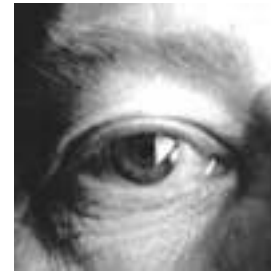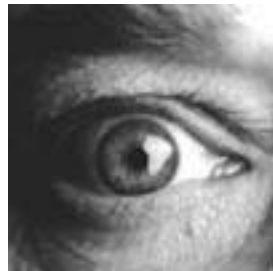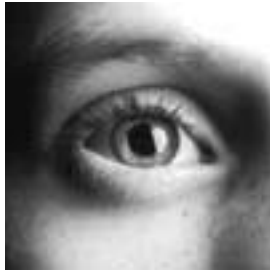The Eye and Vision

- Visual organ – the eye
- 70% of all sensory receptors are in the eyes
- 40% of the cerebral cortex is involved in processing visual information

Recovery Motilities of the Eyes How They Happen

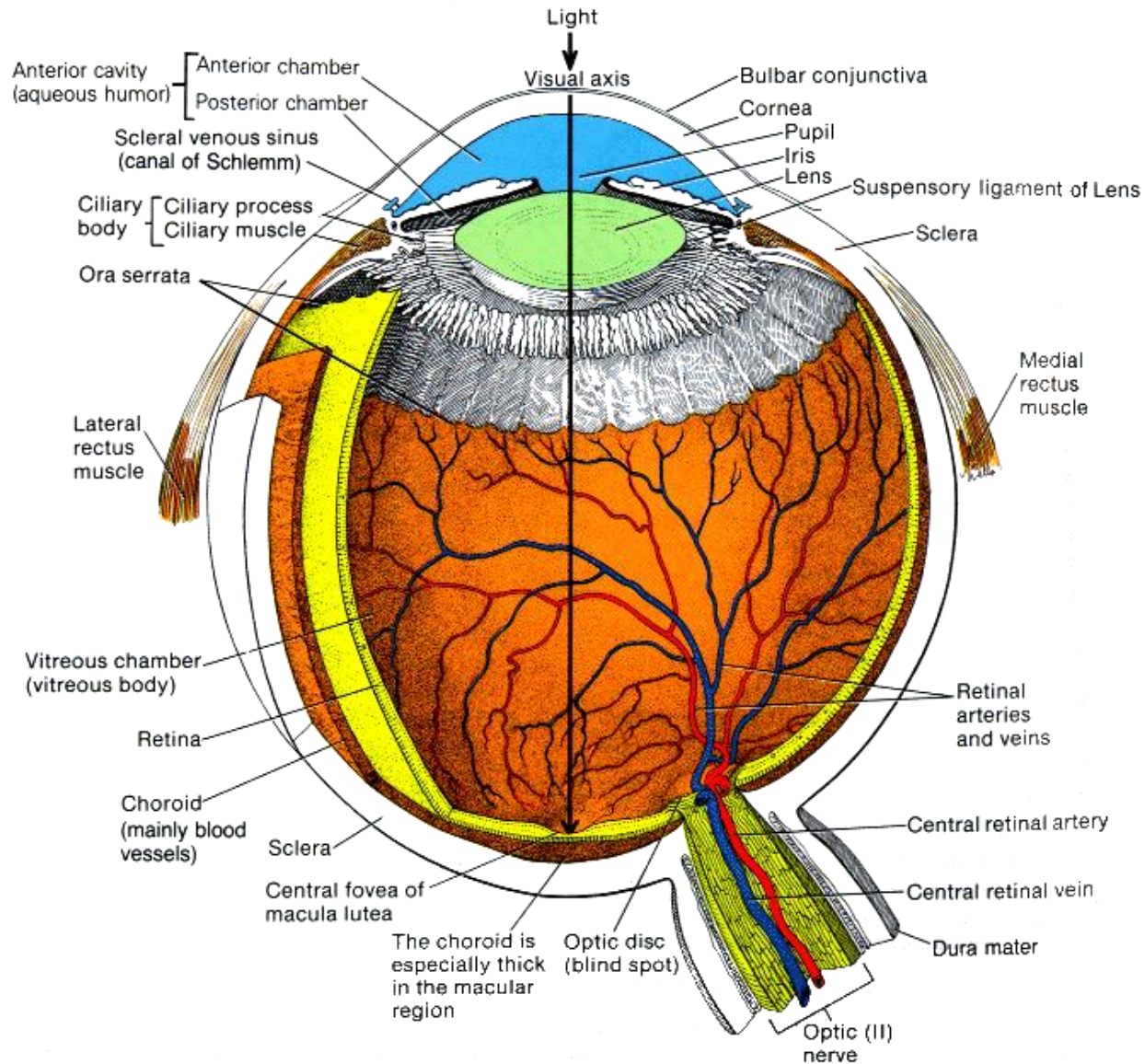


Eyes

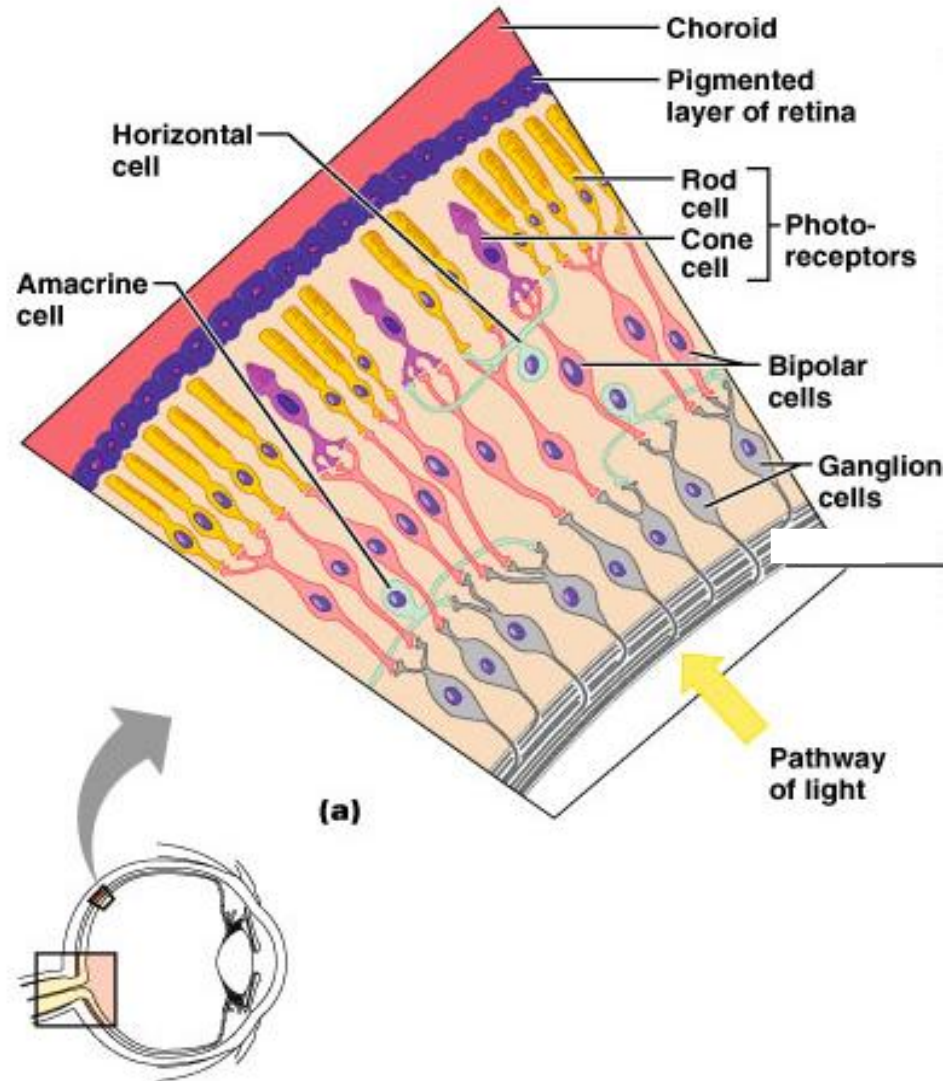


The Eye

www.intomyhealth.com/dr-bob/opti-all/



Microscopic Anatomy of the Retina



Copyright © 2005
Pearson Education, Inc.,
publishing as Benjamin
Cummings

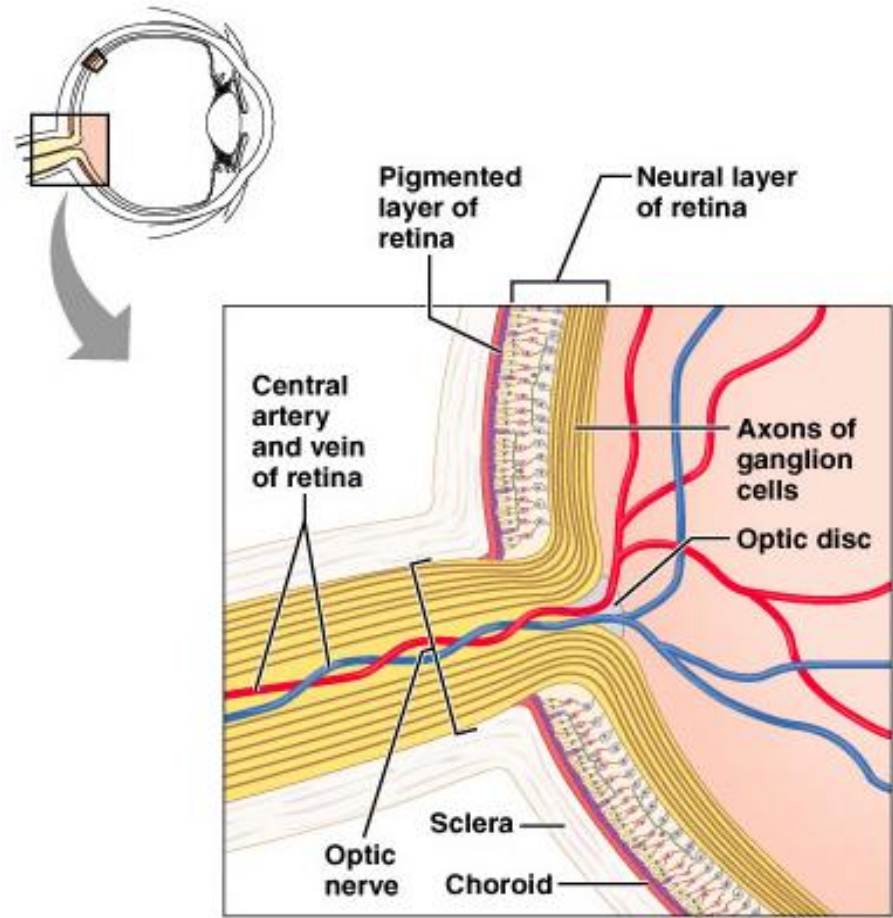
Figure 16.10a

Blood Supply of the Retina

Retina receives blood from two sources:

Outer third of the retina – supplied by capillaries in the choroid

Inner two-thirds of the retina – supplied by central artery and vein of the retina

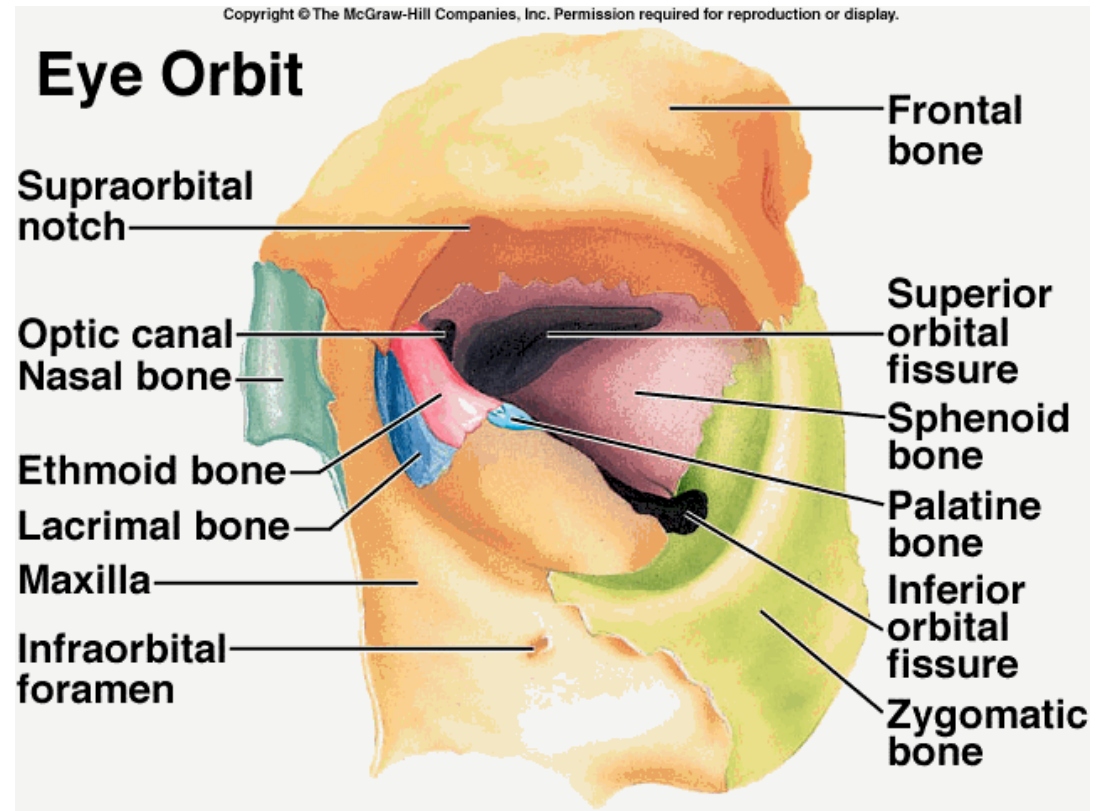


(c)

Consider Bone Bruises of Orbit

www.octc.kctcs.edu/gcaplan/anat/Notes/API%20N...

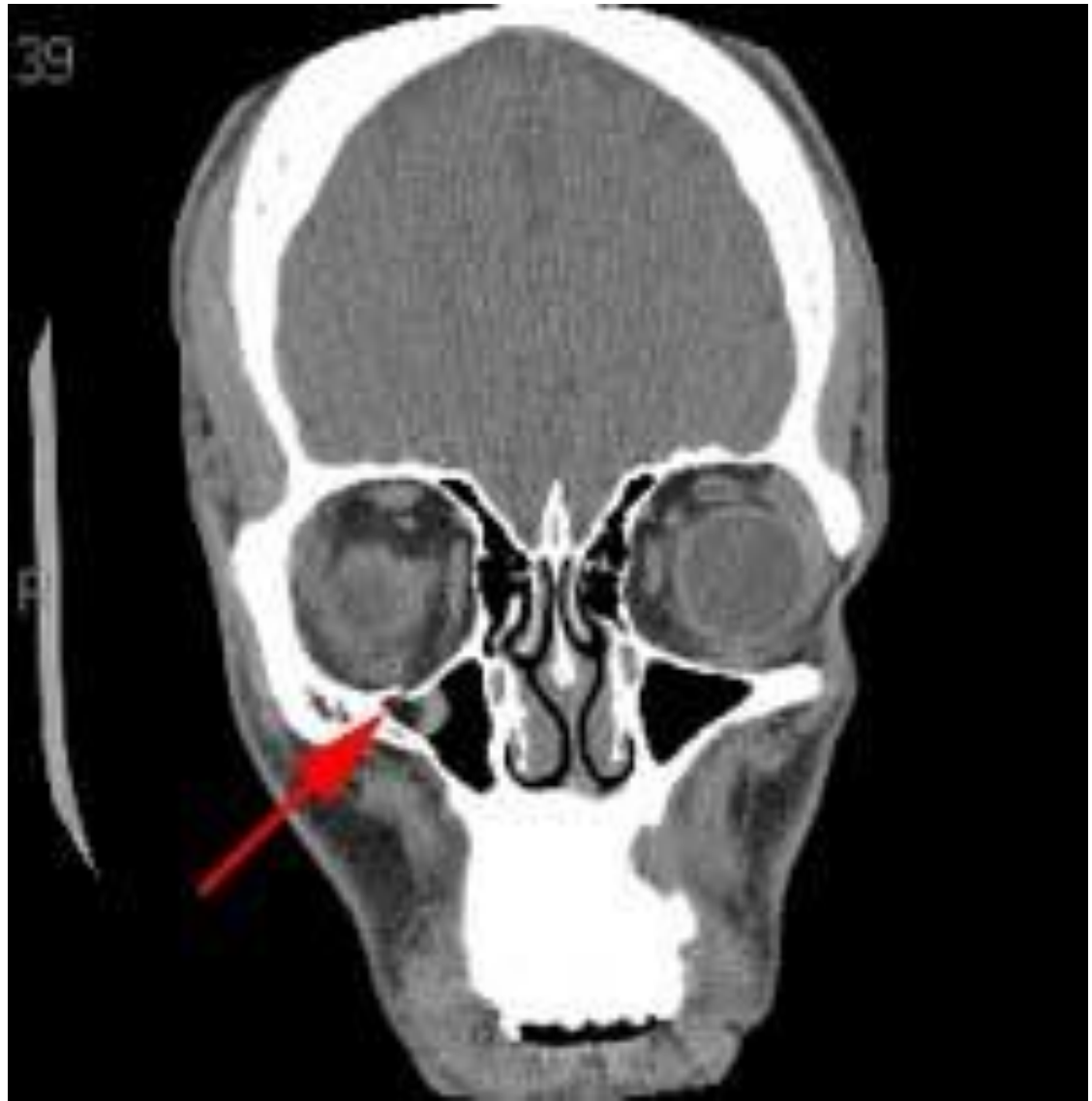
- **Bones:** frontal
sphenoid
zygomatic
maxilla palatine
lacrimal ethmoid
- **Openings:**
optic canal
superior fissure
inferior orbital
fissure



Bone Bruises and Entrapment

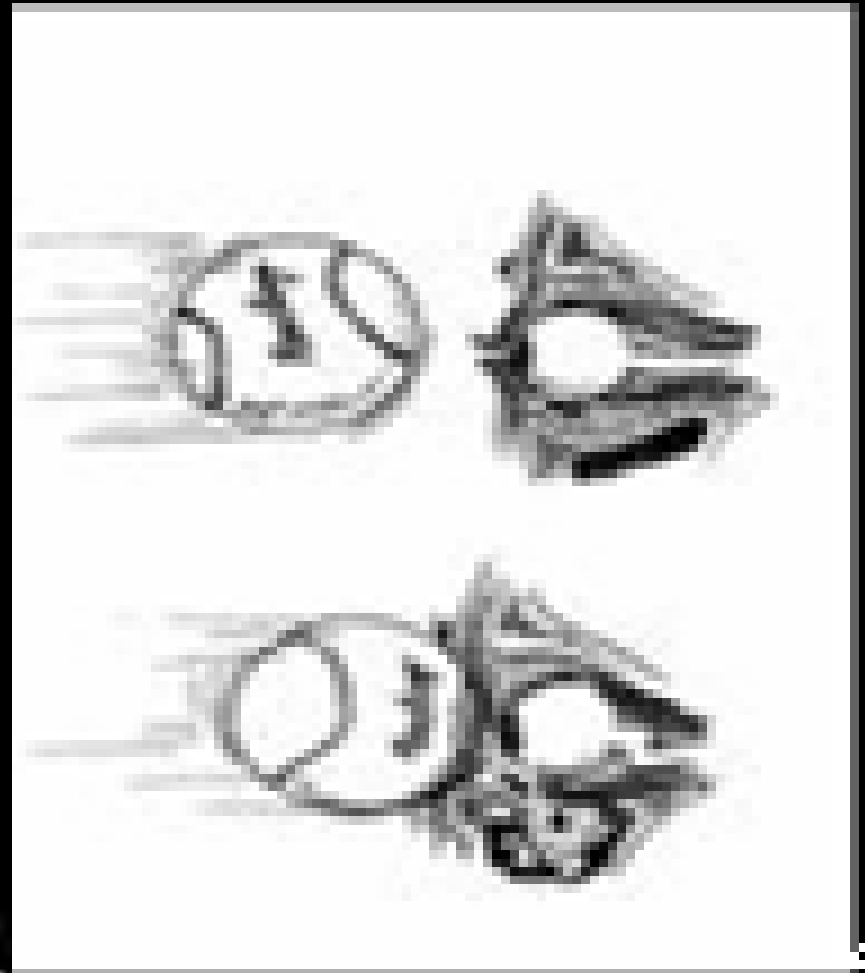
www.warwareyegroup.com/education_orbit.htm

- CAT scan demonstrating a fracture of the bone beneath the right eye with **eye muscle tissue entrapped within the fracture** (arrow).



Blow out Fracture

medpix.net/medpix/parent.php3?mode=display_fa...

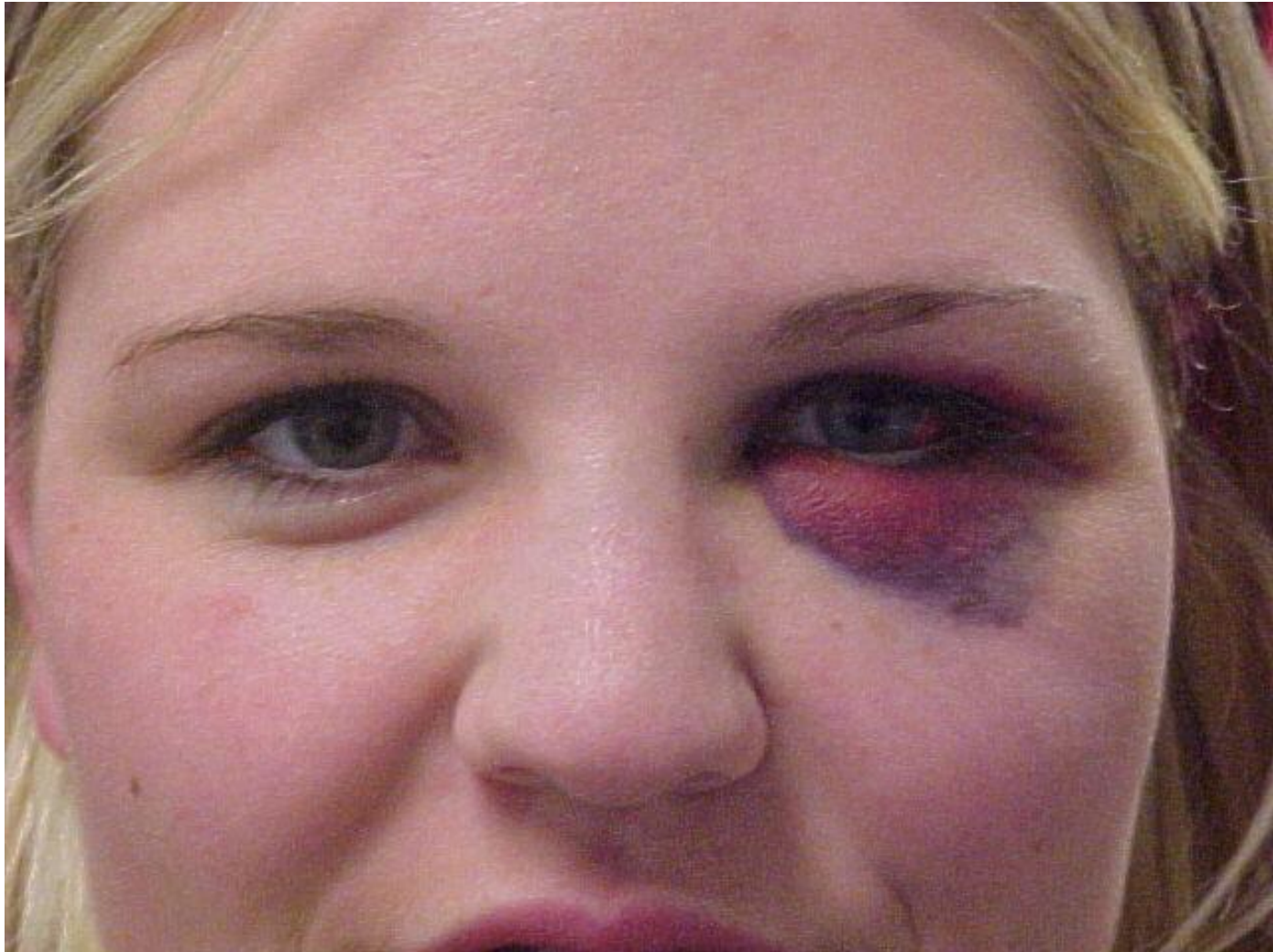

Disruption of Membrane and Fluid Distribution in the Eye

- Bruising
- Pressures
- Macula
- Floaters

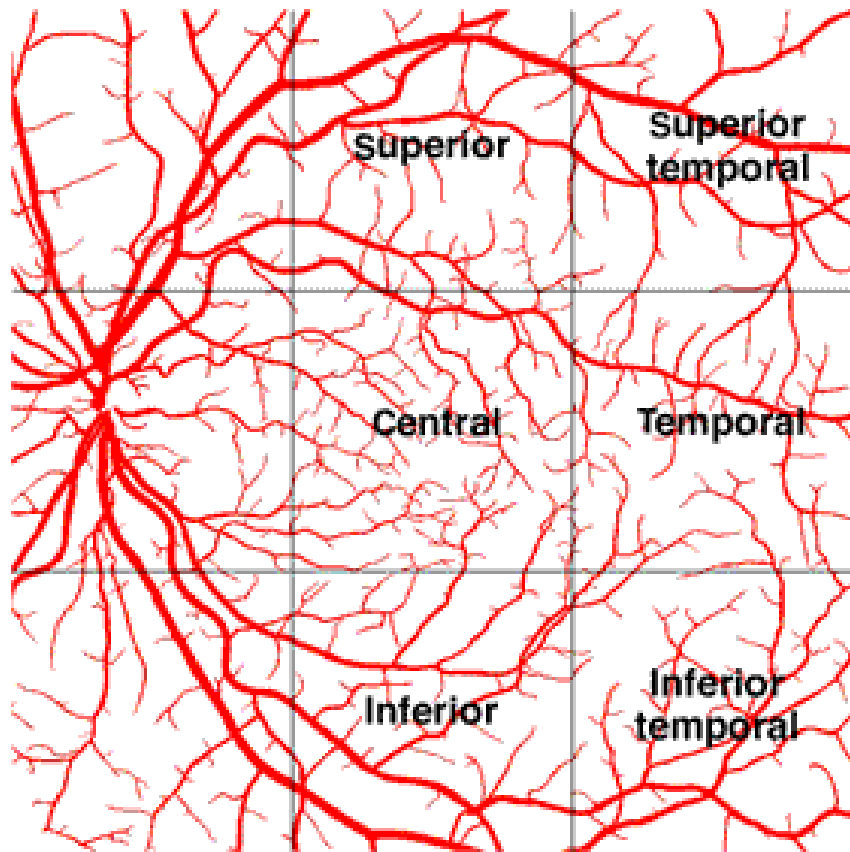
Black Eye and DOMs

www.cheneysd.org/.../sportsmed/injuries.html

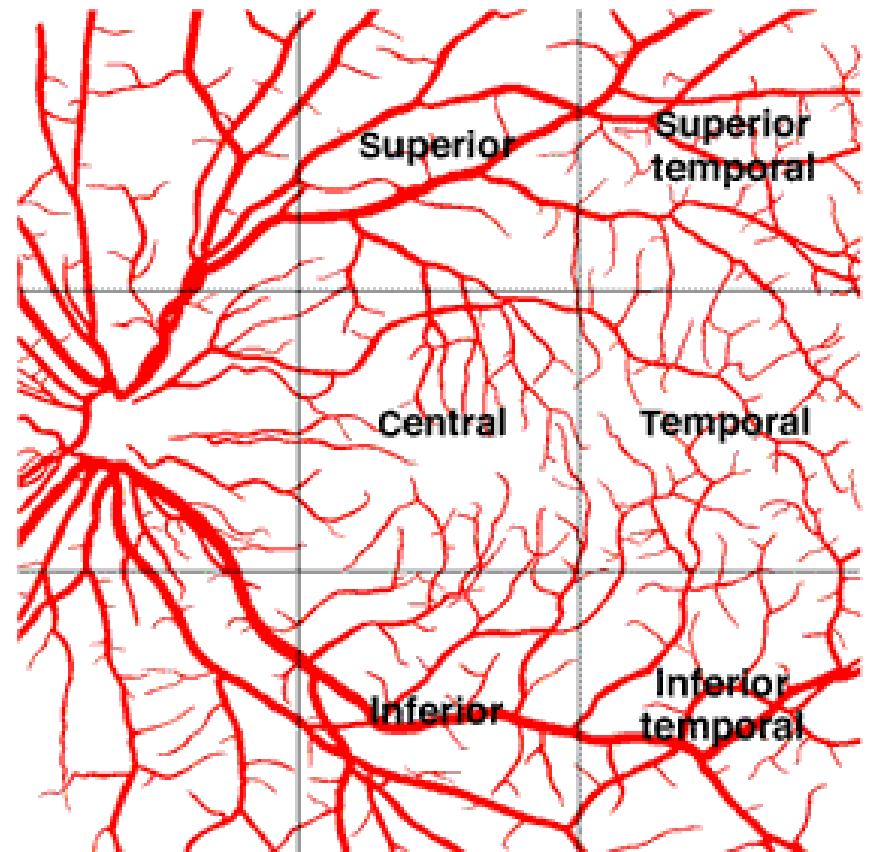


Blood Vessels

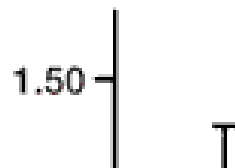
<http://www.fractal.org/Life-Science-Technology/Publications/Fractal-analysis-of-blood-vessels.htm>



Normal retina



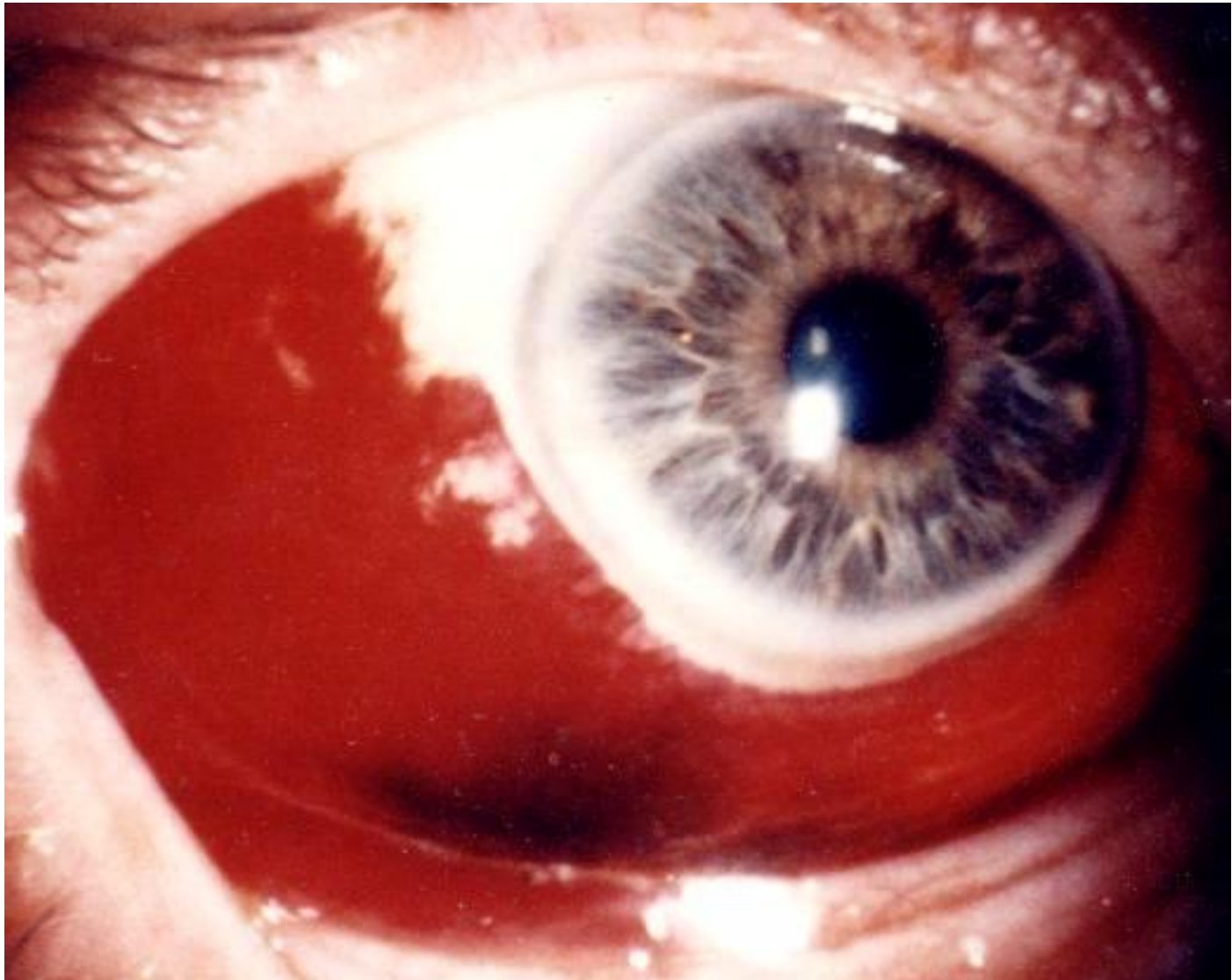
Retina with nonproliferative retinopathy



- Normal
- Nonproliferative diabetic retinopathy

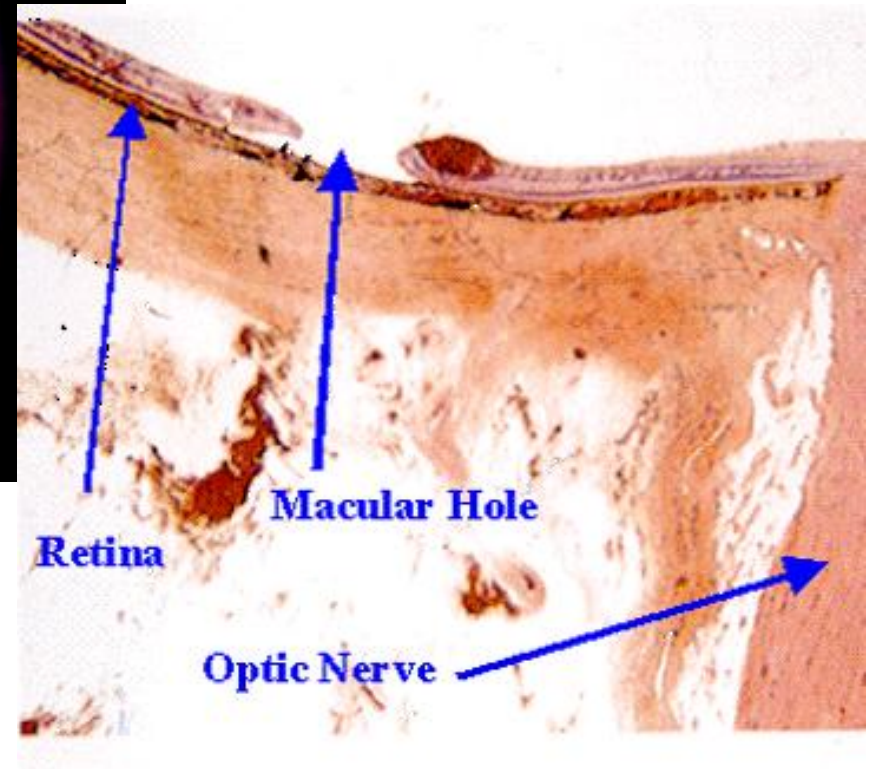
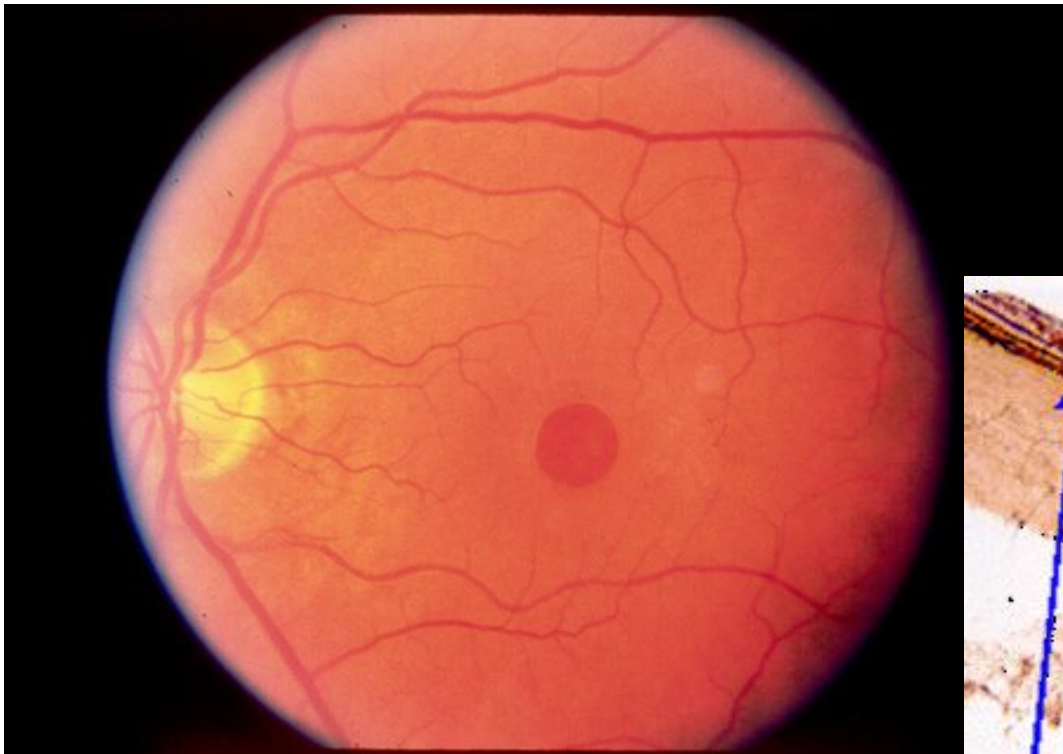Subconjunctival Hemorrhage

www.cheneysd.org/.../sportsmed/injuries.html



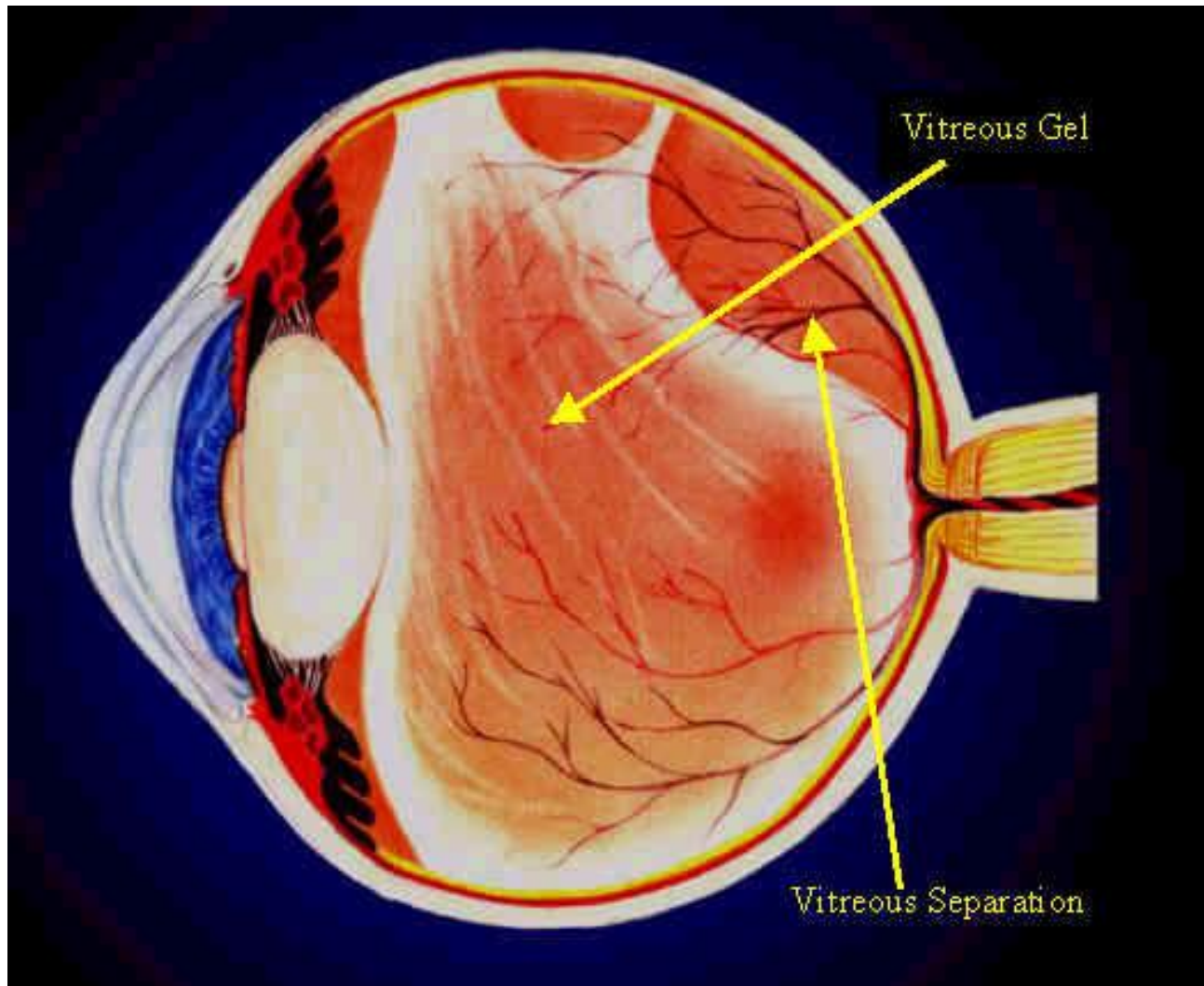
Macular DOMs

www.avclinic.com/macular_hole.htm



Vitreous Tear

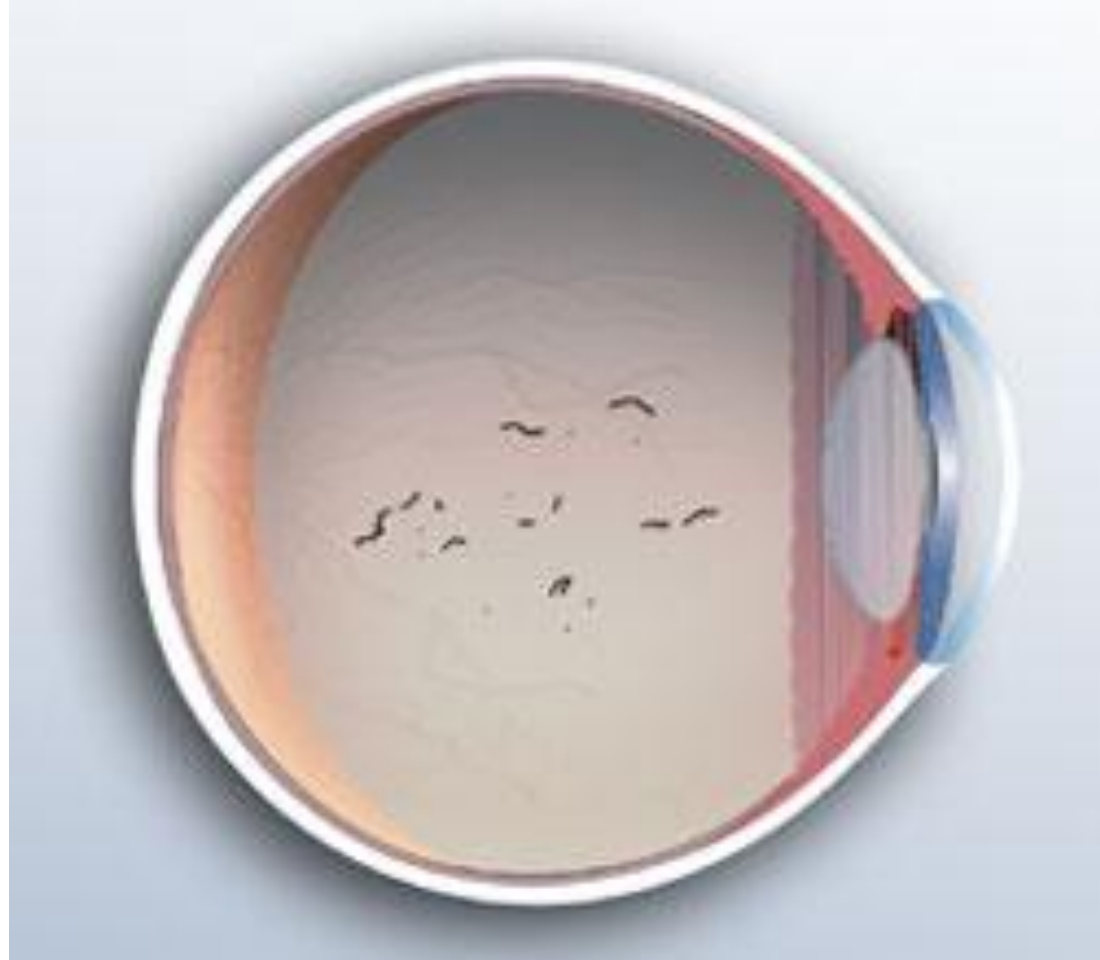www.avclinic.com/macular_hole.htm



Vitreous Detachment and Floaters

www.eyesoncharlotte.com/.../flashesfloaters

- As you get older, the **vitreous gradually becomes thinner or more watery**. By the time you are in your twenties or thirties, the vitreous may be watery enough to allow some of the **clumps and strands to move around inside the eye**. This material floating inside the eye can **cast shadows on the retina**, which you see as small floating spots.



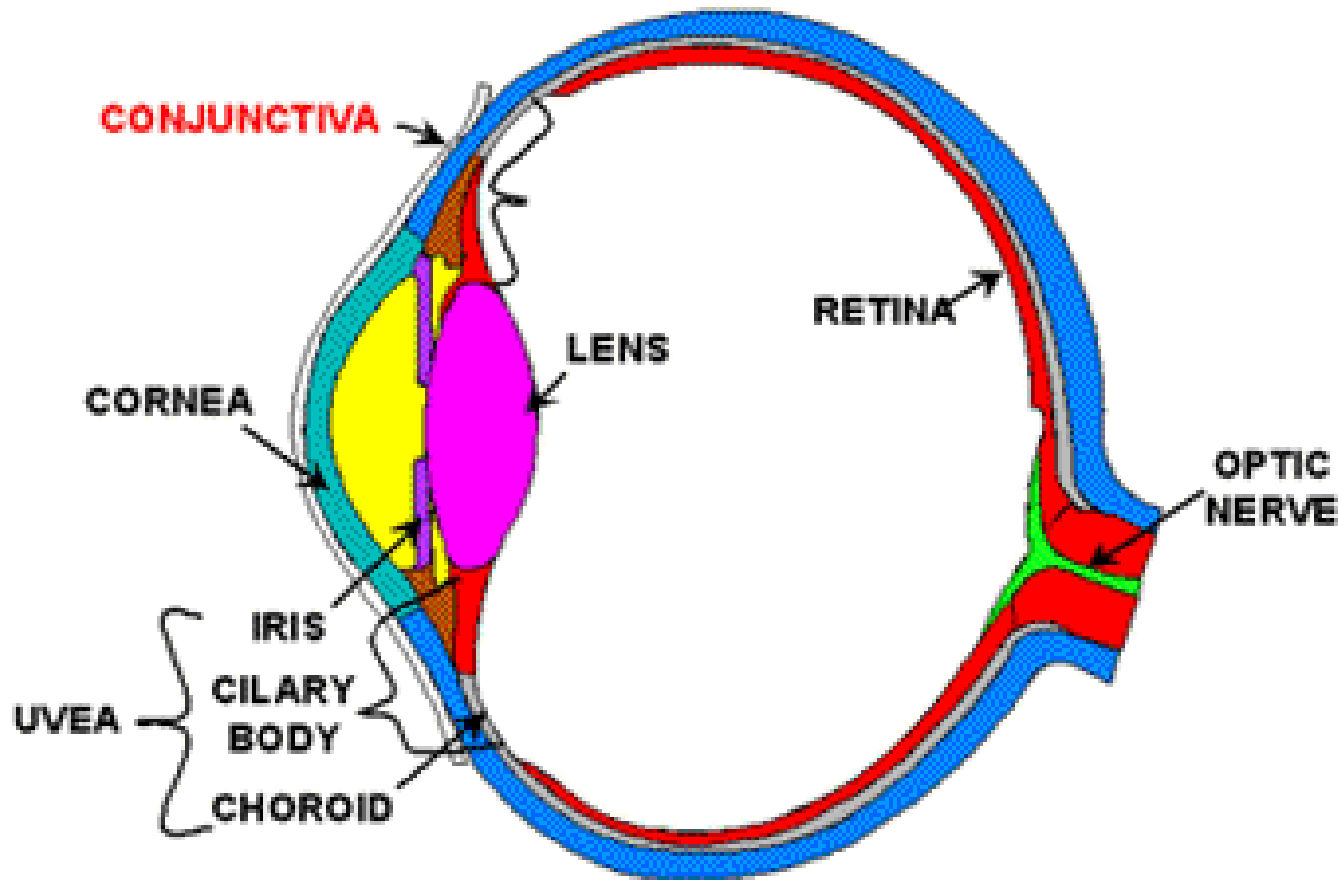
Inflammation

- Inflammation of the Eye
 - Conjunctivitis
 - Keratitis
- Disruption of Membrane
 - Trauma
 - Corneal Ulcers

The Eye

www.brucrosemanmd.com/id53.htm

STRUCTURES OF THE EYE



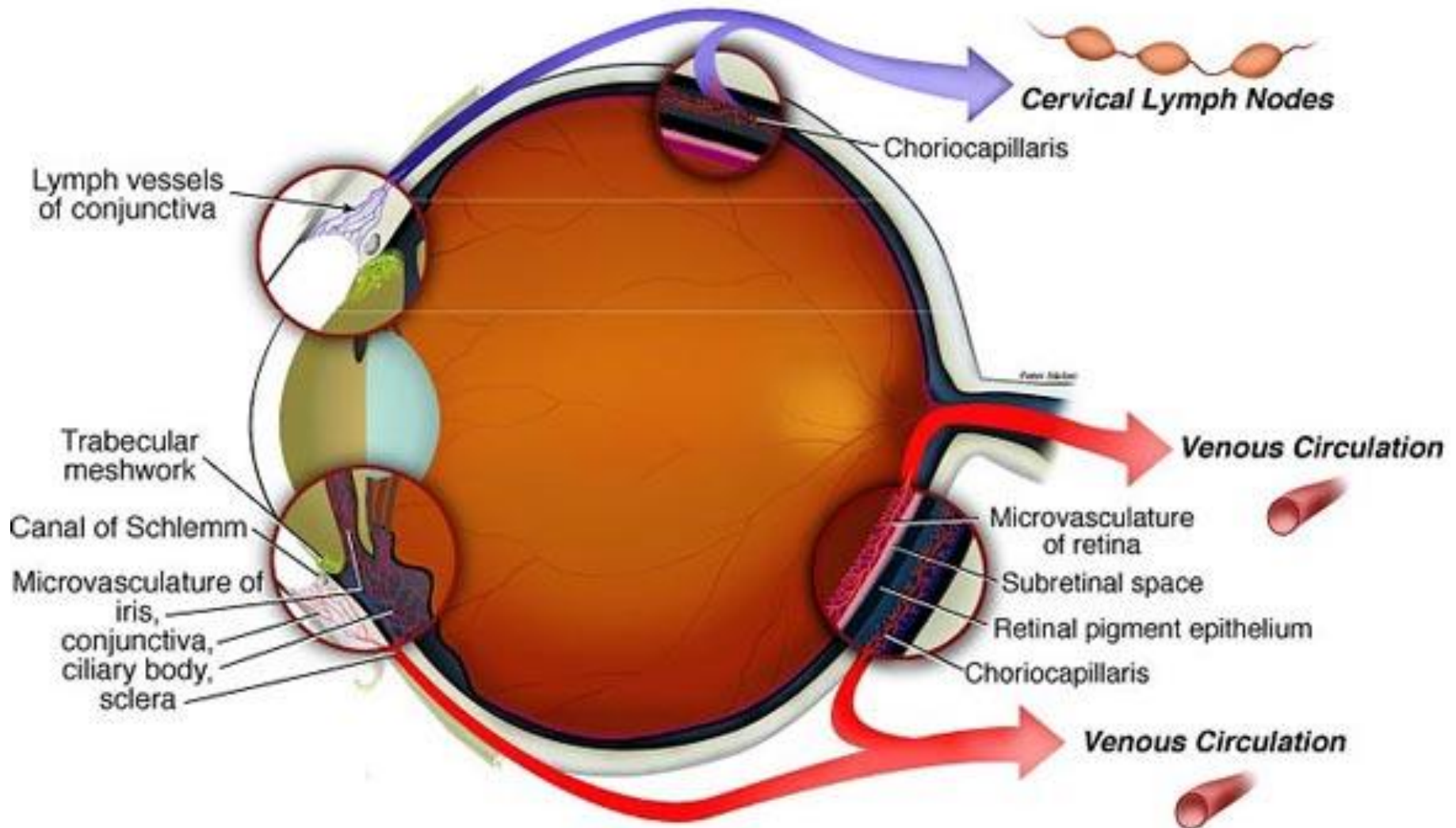
Inflammations

emcritcare.org/065-132/066-eye.htm

- **Iritis and Uveitis**: Miosis of affected pupil, can be irregularly shaped with limbic blush; Consensual Photophobia-pain in affected eye when light shined in opposite;
- Pain c Accommodation-look far then at your finger; Will have cells (sparkles) and flare (smoke) on slit lamp exam; Visual loss until resolution is frequent
- **Episcleritis**: Usually presents acutely; self-limited disease lasting 7 to 10 days (sometimes longer); not usually associated with pain or systemic disease
- **Scleritis**: Sign of systemic disease; Sclera may look blue or purple because you can see through to vessels
- Bulbar conjunctiva red out of proportion to palpebral conjunctiva; usually develops over days to weeks; insidious; deep boring pain and tender eye; diagnosis made by history and palpation; look for deep violaceous hue (putting phenylephrine in eye will shrink superficial vessels but not deep vessels); usually associated with systemic diseases; patient needs workup by ophthalmologist; can be associated with rheumatoid arthritis, Wegner's granulomatosis, polyarteritis nodosa, syphilis
- **Endophthalmitis**: Infection of deep eye structures, usually post-operative.
- Non-visible fundus; Horrible risk for poor outcome

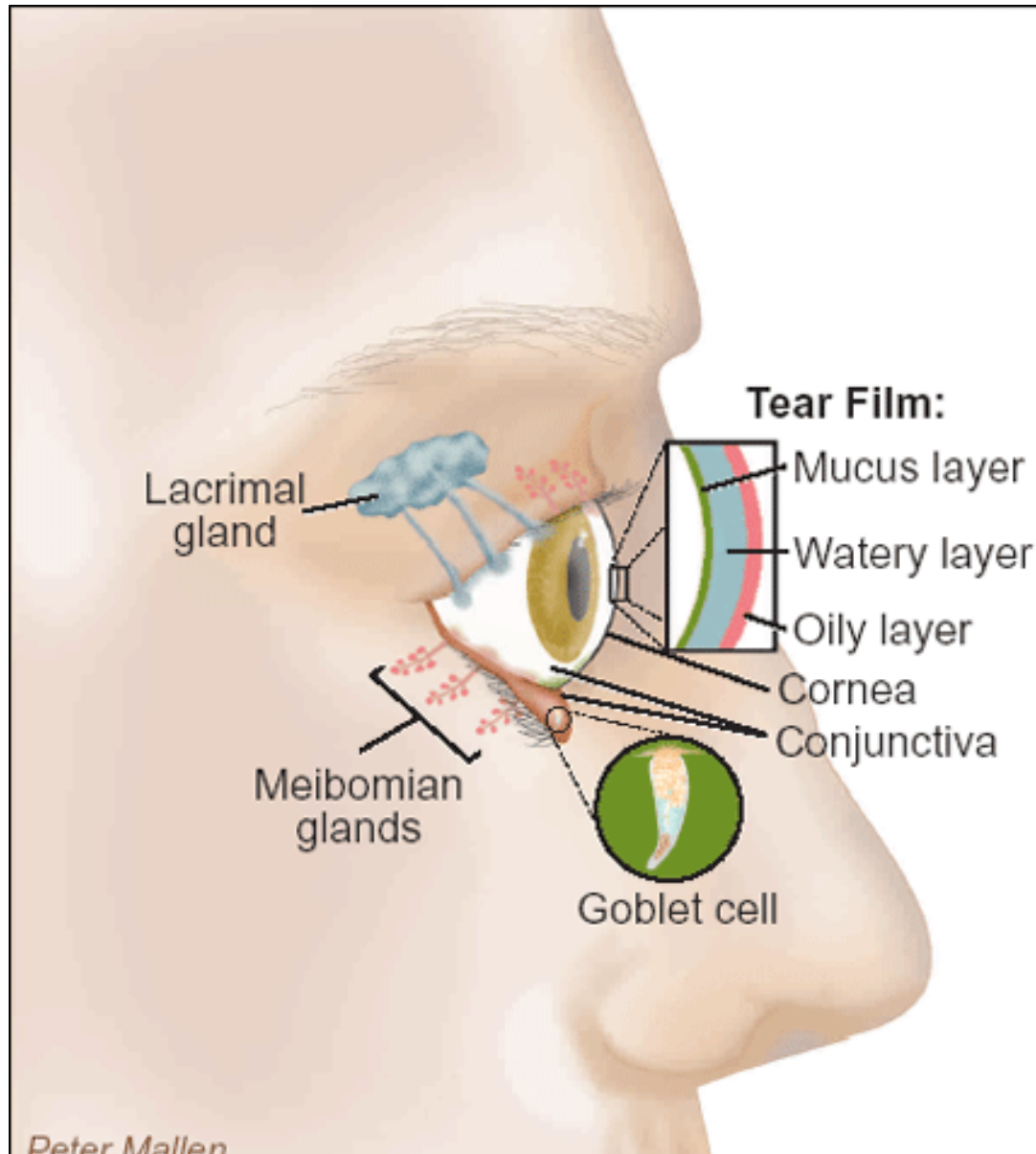
Lymph Drainage of the Eye

www.theschepens.org/faculty/streilein/immunobiologyofcornealtransplants.htm



Tear Production and Dry Eyes

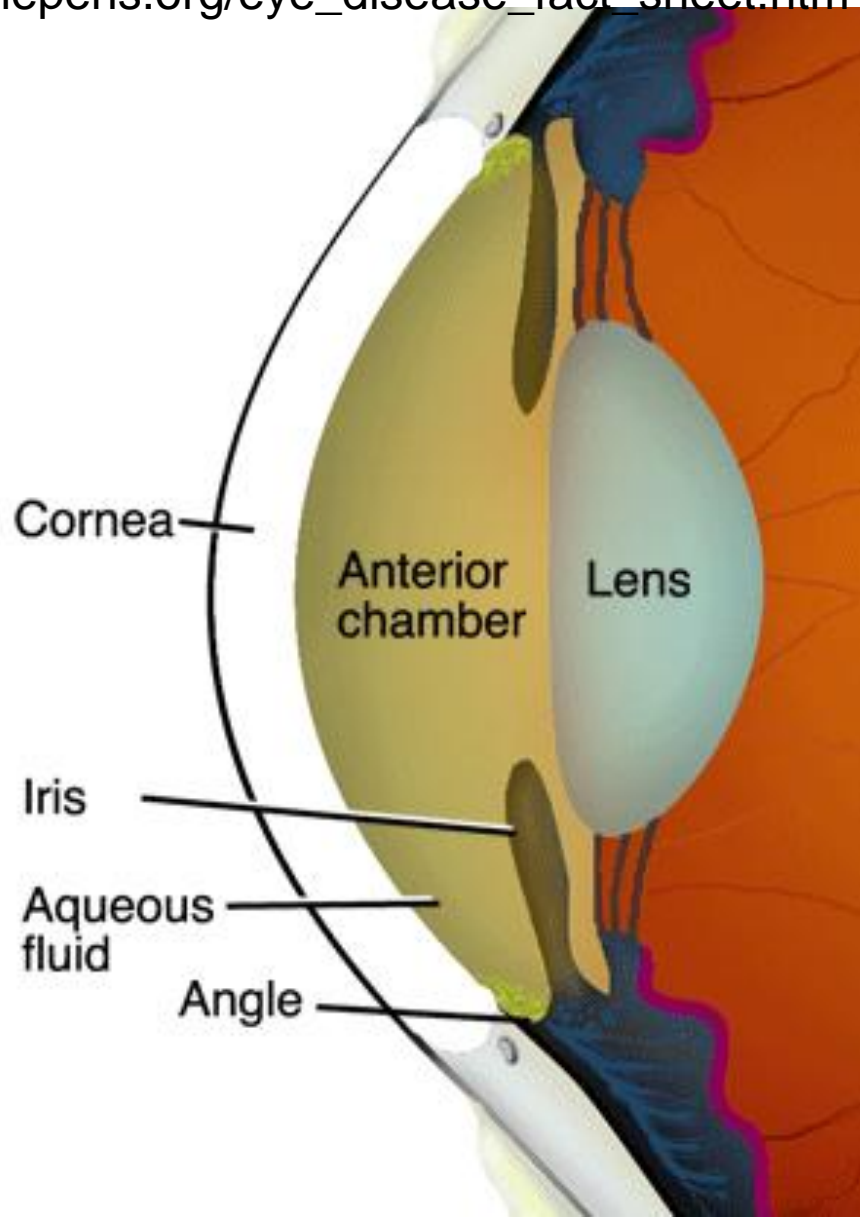
http://www.theschepens.org/eye_disease_fact_sheet.htm



Circulation of Aqueous Fluid

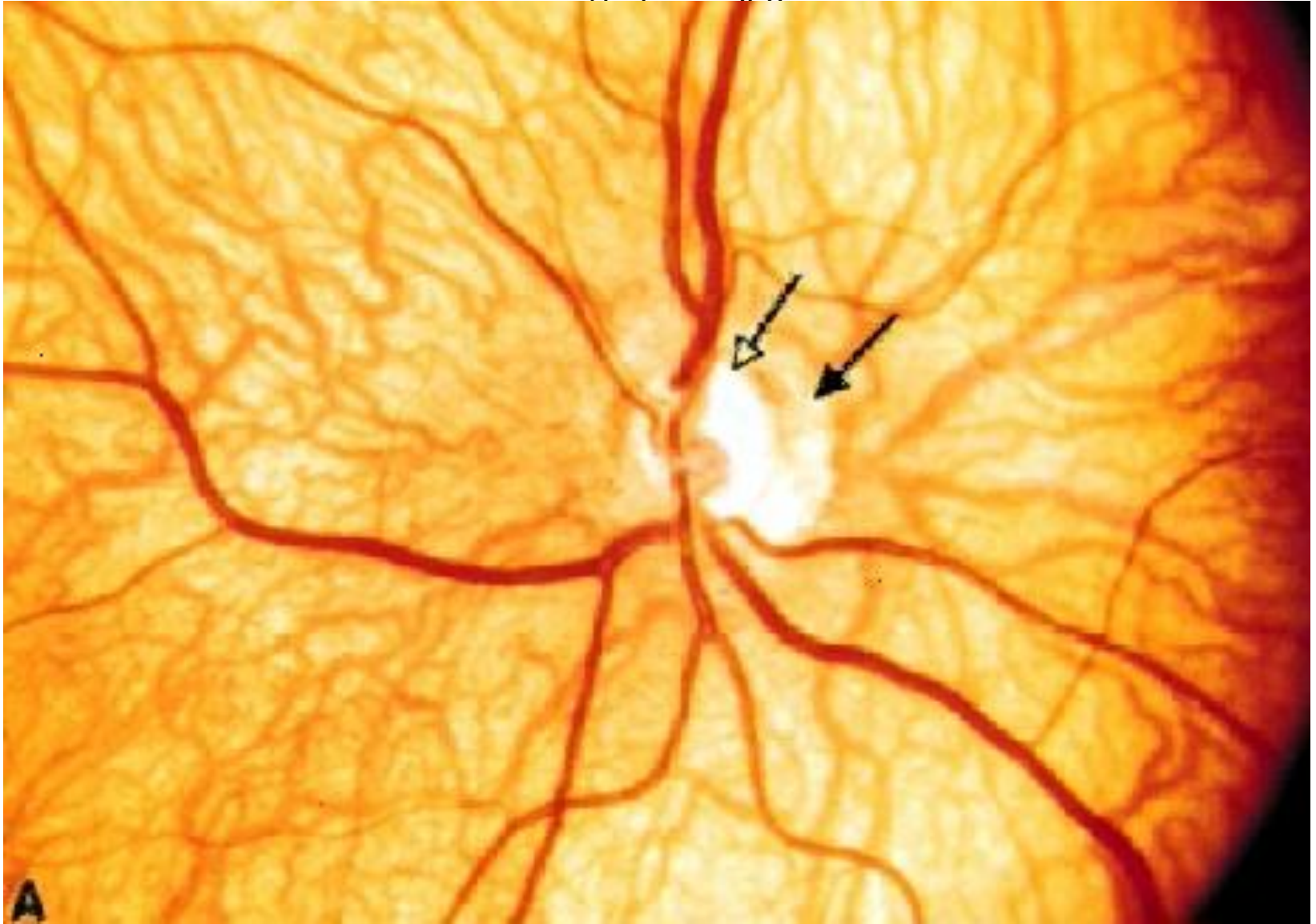
http://www.theschepens.org/eye_disease_fact_sheet.htm

- The path of aqueous fluid, from its formation in the ciliary body through its exit from the eye.



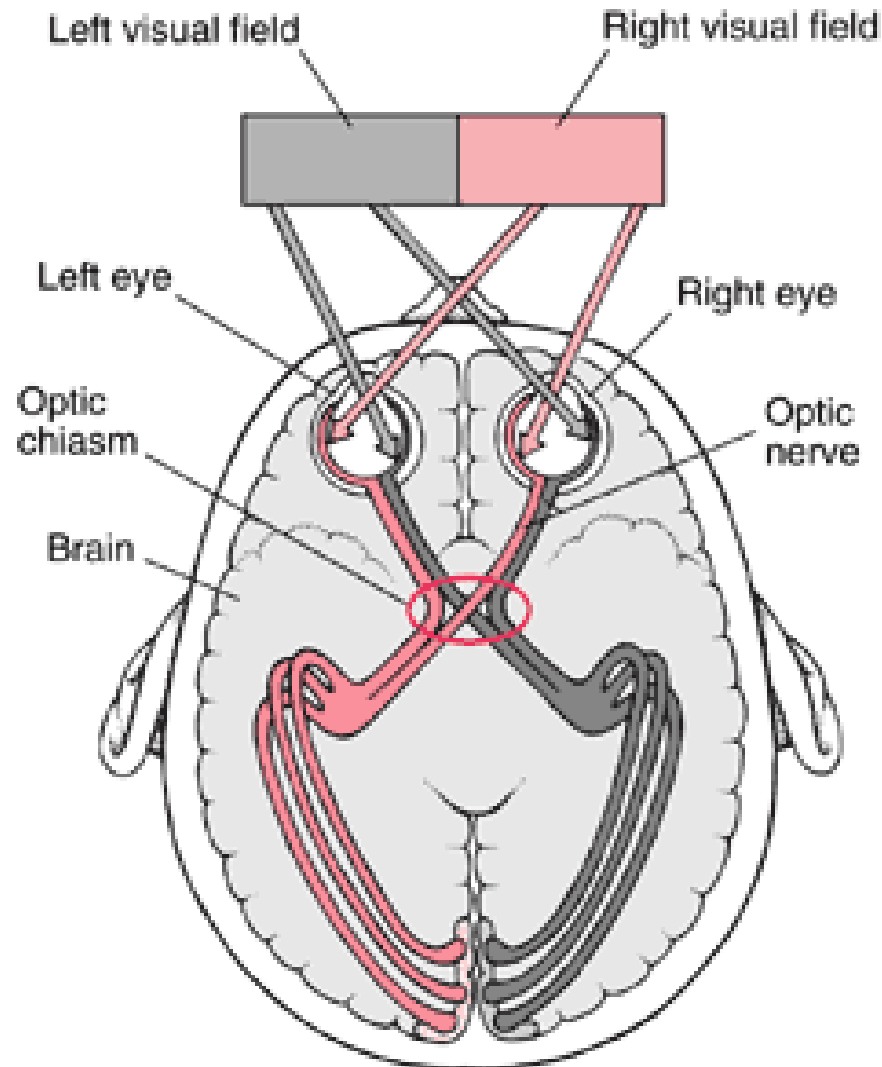
Optic Nerve Hypoplasia

<http://www.bashour.com/examprep/documents/Flash%20Card%20Files/optic%20nerve%20hypoplasia.jpg>



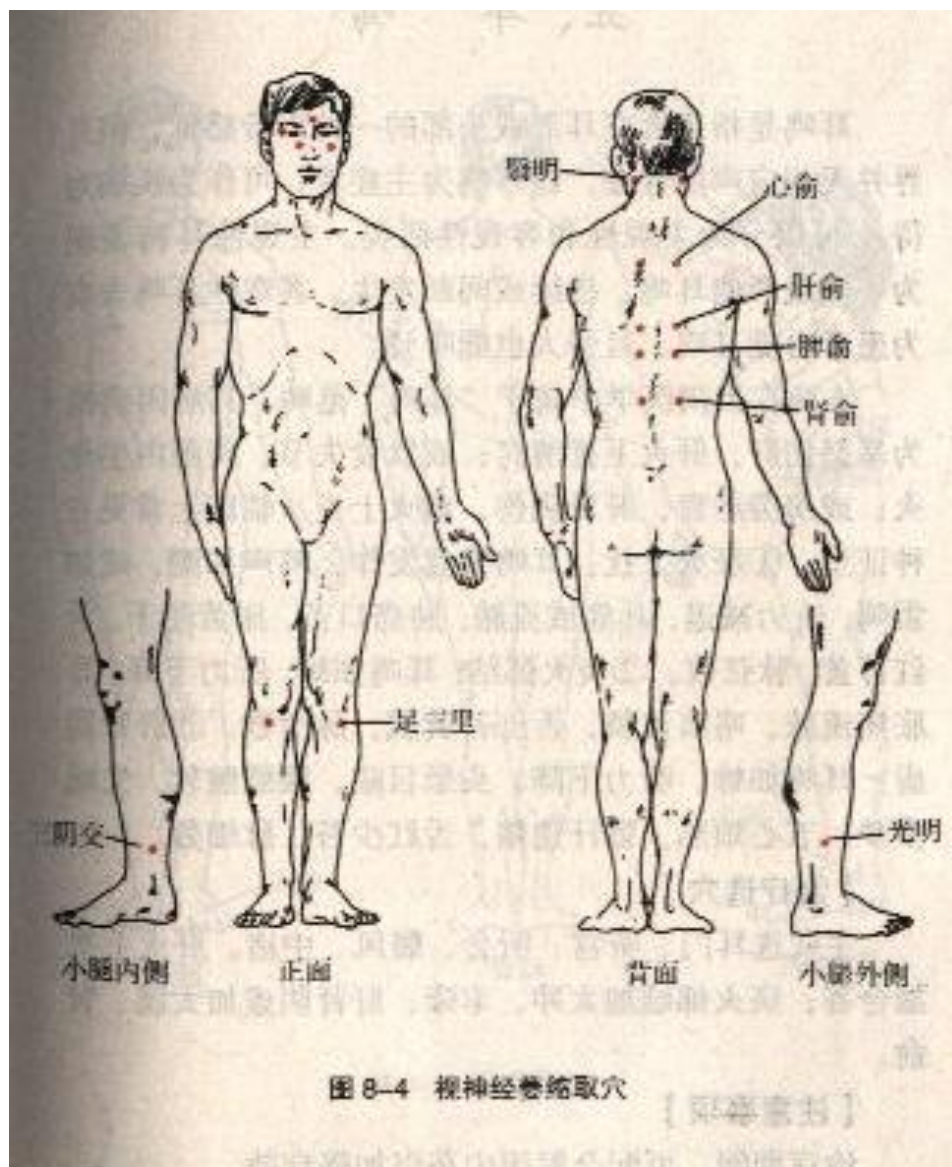
Optic Nerve

www.merck.com/mmhe/print/sec20/ch235/ch235a.html



Cupping Therapy for Optic Nerve Atrophy

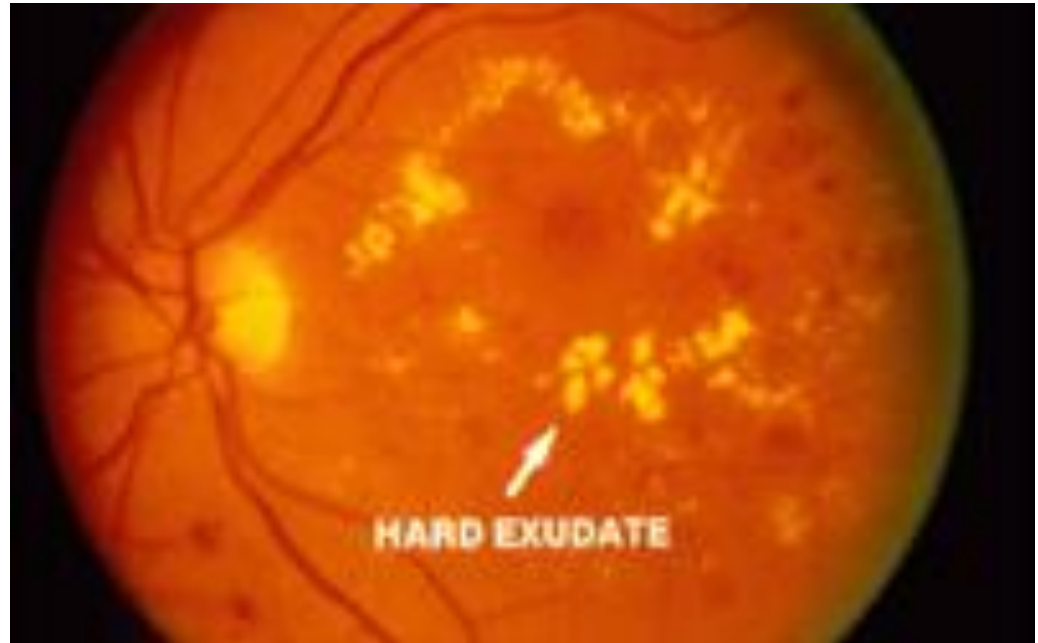
www.chinainbook.com/.../optic_nerve_atrophy.htm



Hard Exudate in Diabetic Retinopathy

www.legarretaeyecenter.com/diabetic-retinopat...

- The earliest changes in diabetic retinopathy are abnormalities in the blood vessel walls that cause outpocketings, known as **microaneurysms**. These ballooned out areas may leak out protein, fat, fluid or blood. These leaking blood vessels may or may not effect vision. If they are located on or near the macula where all the fine vision is **located then it is known as** diabetic macula edema and can cause a significant reduction of vision. In proliferative retinopathy abnormal new blood vessels may grow or proliferate over the retinal surface and optic nerve.



- These new blood vessels, however, are very fragile and tend to break easily and hemorrhage. The hemorrhaging can cause all kinds of problems and reduction in vision. These new blood vessels may shut down and scar.
- **The scarring may cause pulling of the retina leading to a retinal detachment.**

Normal Vision



Myopia / Near Sightedness



- A scene as it might be viewed by a person with Myopia (Near Sightedness)
- National Eye Institute, National Institutes of Health
- www.nei.nih.gov

Dyslexia

"When Michael first started school at the age of 5, his writing was appalling. You could hardly read a thing he wrote," says his mother. "He went from being a happy child to being very unhappy, miserable, tearful, because he just couldn't understand why all those children around him could pick up this business of reading and writing." Michael's teachers simply thought he was taking a little longer than the other children—that he'd catch up. It was three years before anyone realised that he was dyslexic. Now, at the age of 18, Michael has the reading age of a 12-year-old and the spelling ability of a 10-year-old.

Words can be hard to read for several different reasons

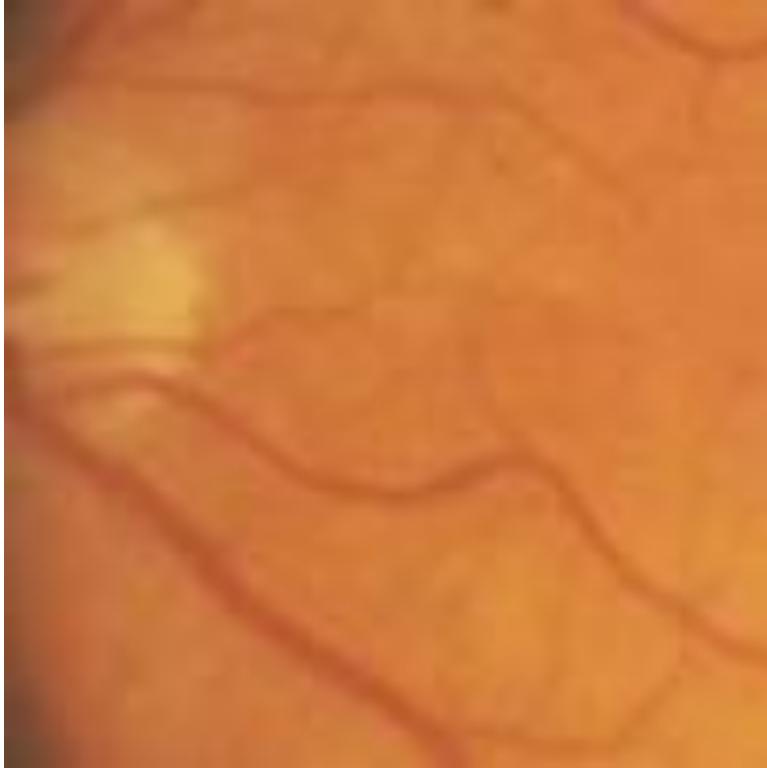Words can be hard to read for several different reasons

Cataracts



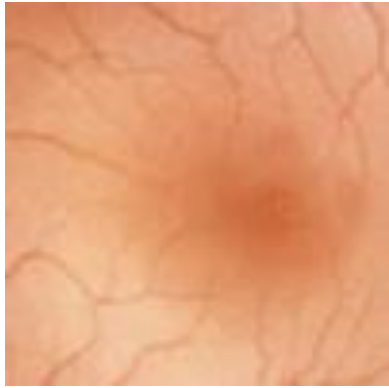
- A scenes as it might be viewed by a person with cataracts
- National Eye Institute, National Institutes of Health
- www.nei.nih.gov

Retinopathy

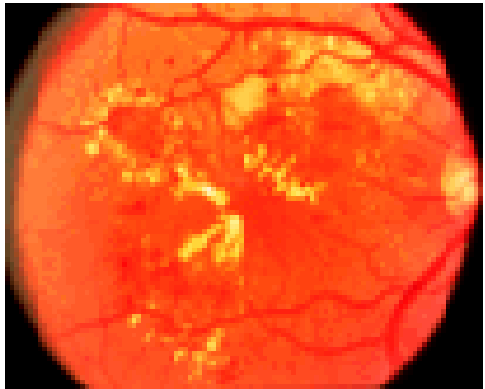


- In background retinopathy, a slight deterioration in the small blood vessels of the retina, portions of the vessels may swell and leak fluid into the surrounding retinal tissue.
- National Eye Institute, National Institutes of Health
- www.nei.nih.gov

Diabetic Retinopathy



- Normal Fundus (Top)
- Fundus in Diabetic Retinopathy (Bottom)



Diabetic Retinopathy

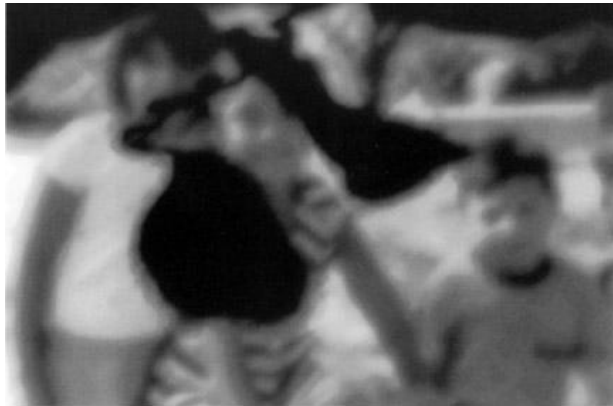


- A scenes as it might be viewed by a person with Diabetic Retinopathy
- National Eye Institute, National Institutes of Health
- www.nei.nih.gov

Diabetic Retinopathy



Visión normal

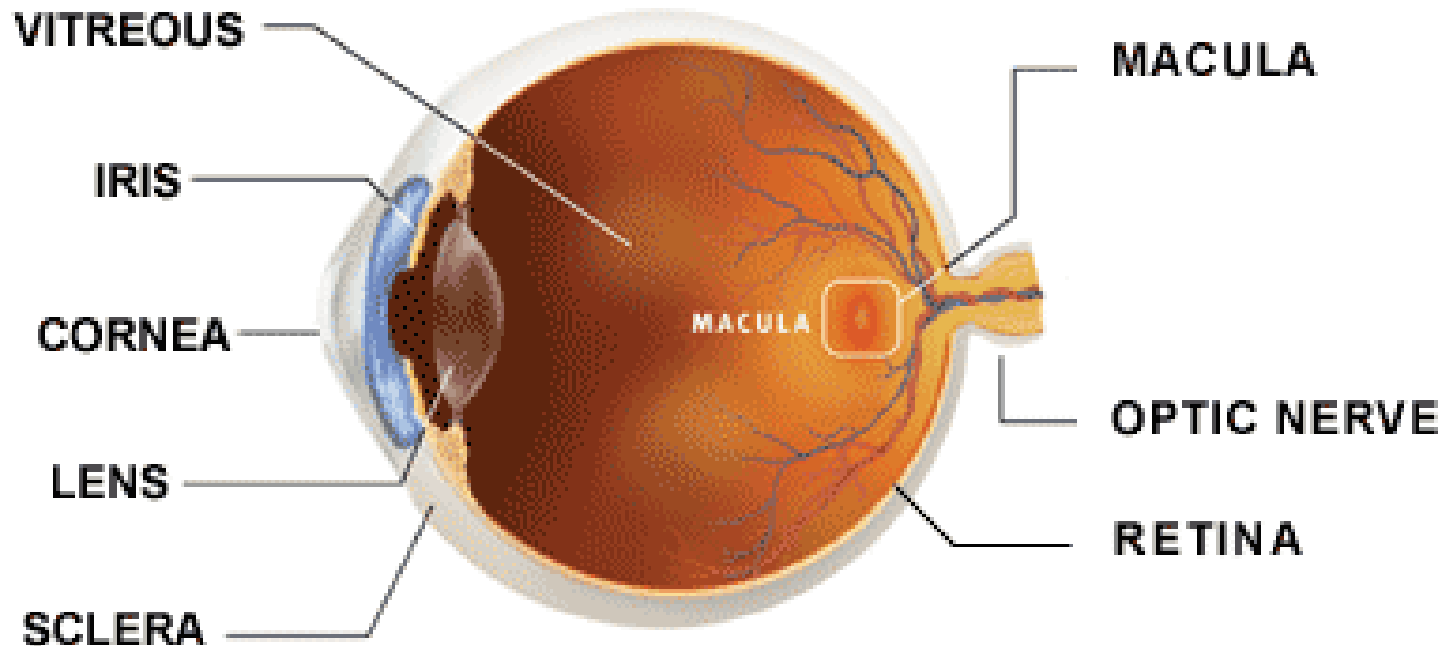


La misma toma como pudiese ser vista por una persona con retinopatía diabética.

- A scenes as it might be viewed by a person with Diabetic Retinopathy
- National Eye Institute, National Institutes of Health
- www.nei.nih.gov

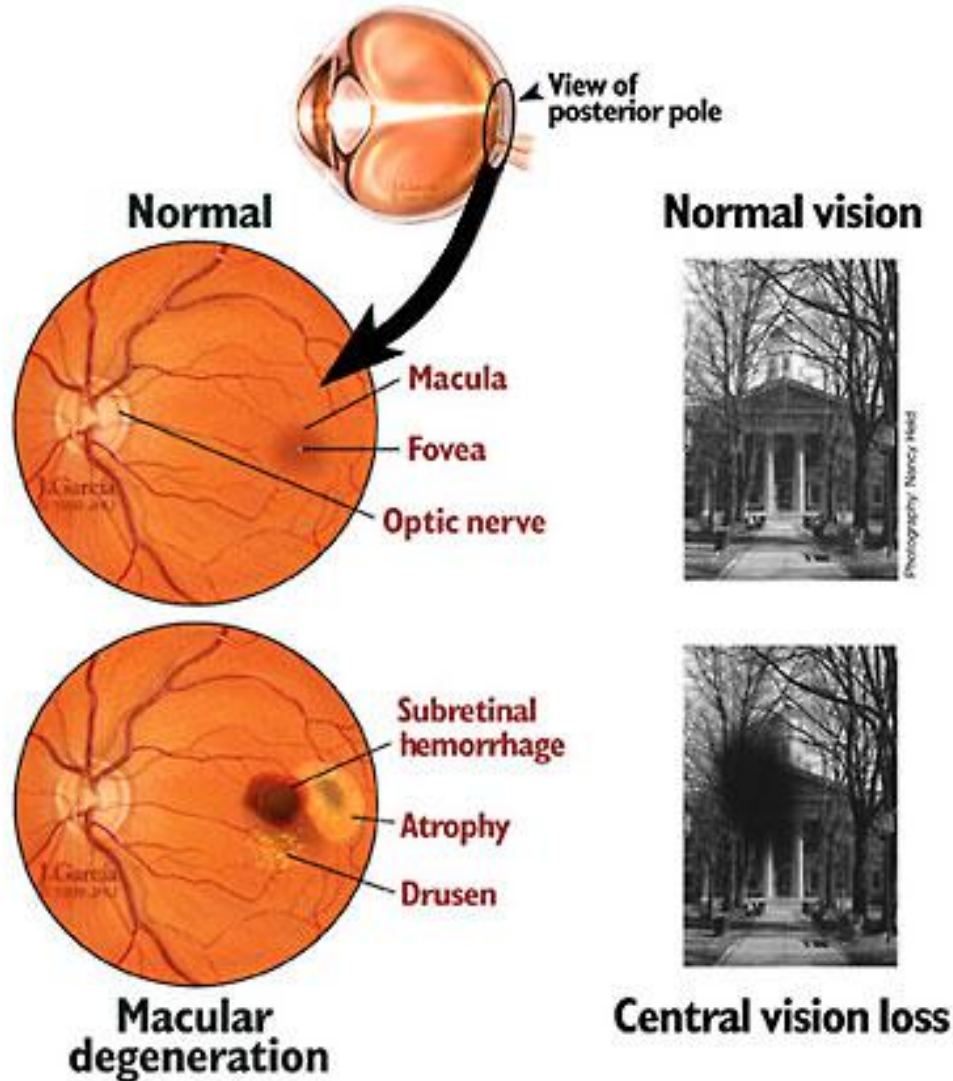
Macular Degeneration and DOMs

www.brucerosemanmd.com/id53.htm



- **Wet macular degeneration:** The more serious type of macular degeneration, where weak blood vessels form under the macula. The blood vessels break and leak blood and fluid, which leads to central vision loss (loss of images seen from the center of the eye).

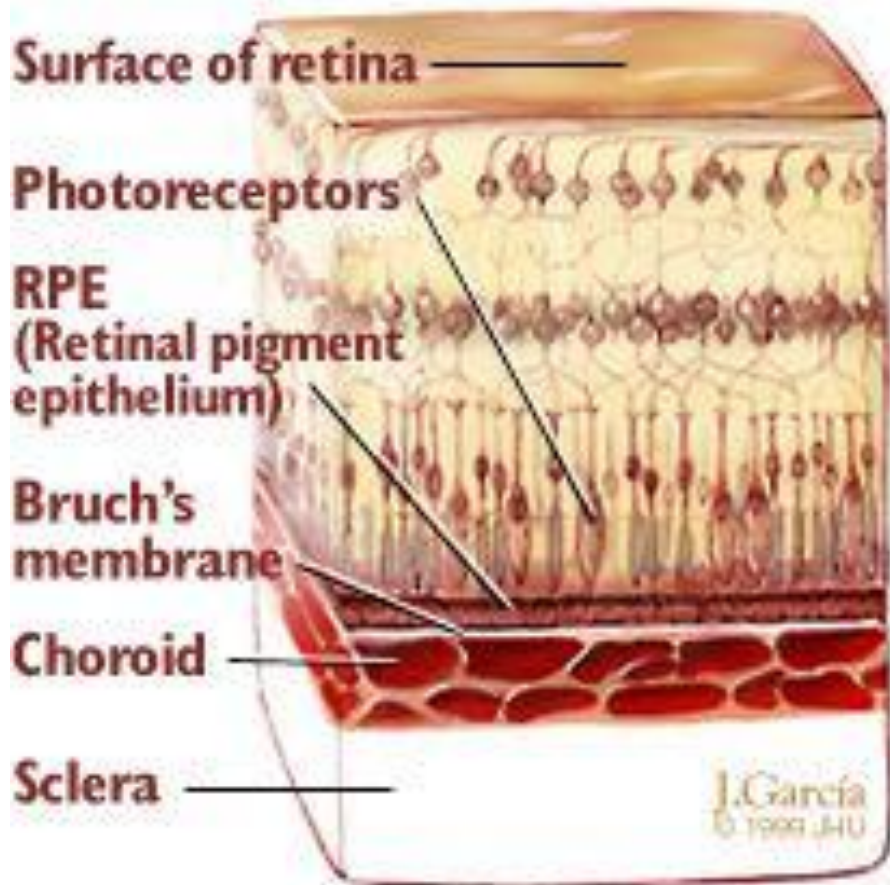
Macular Degeneration



- Age-related macular degeneration (AMD) is a major public health problem. It is the most common cause of visual loss in developed countries in individuals over the age of 60. It is estimated that by the year 2000, more than 2 million people in the United States will be afflicted with this serious sight-threatening disorder. (Wilmereyeyeinstitute.net)

Macular Degeneration

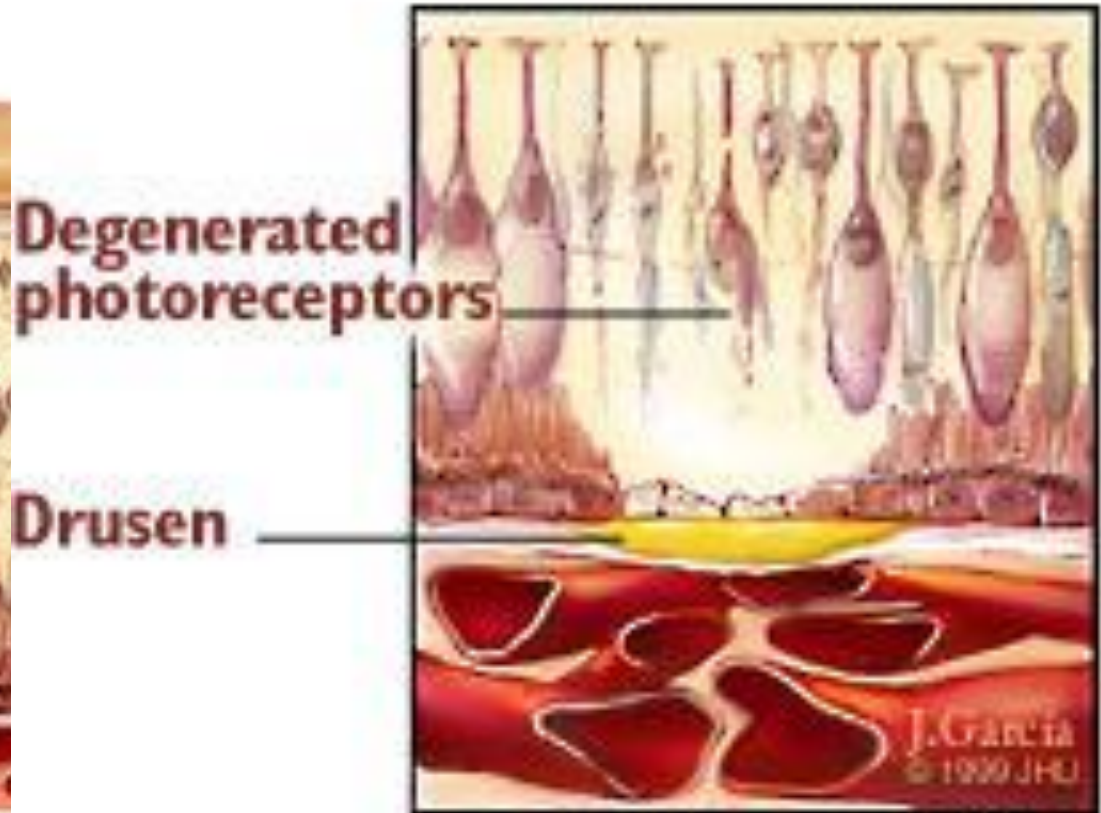
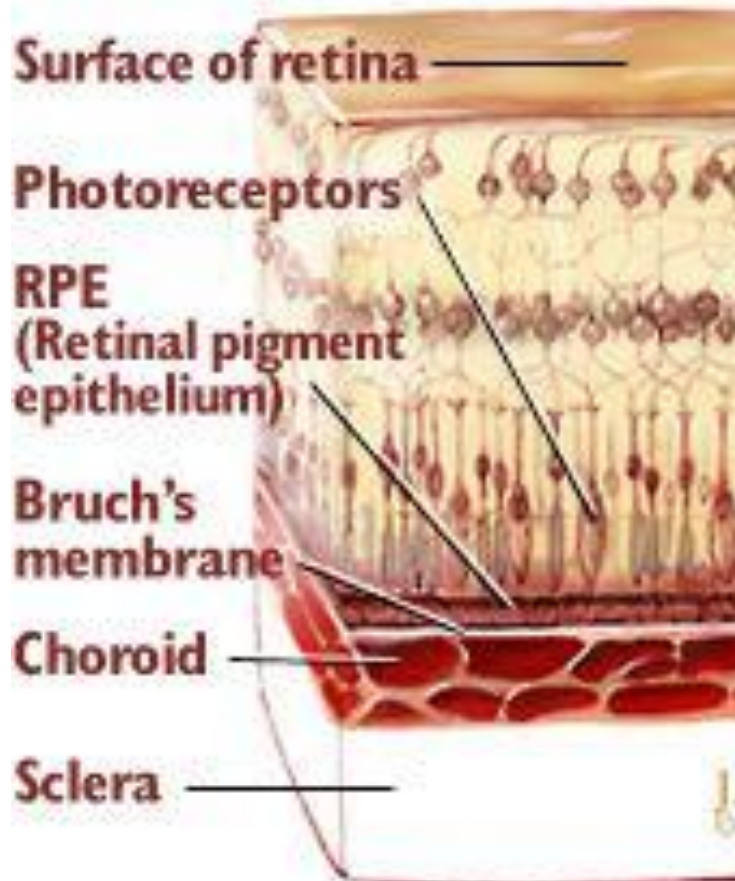
Anatomy of retina and posterior eye



The retina is a complicated network of nerve cells that changes light into nerve impulses that travel to the brain where they are interpreted as visual images. The central part of the retina is called the macula and is responsible for vision that is needed for reading and other detailed work. Damage to the macula results in poor vision. The most common disease process that affects the macula is age-related macular degeneration (AMD). In patients with AMD, retinal cells in the macula die over the course of several years. The cell death and gradual visual loss usually do not begin until age 60 or older and hence the name age-related macular degeneration. It is not known why the cells die, but two clues suggest that genetic defects called mutations may be involved. One clue is that AMD runs in families and another clue is that AMD shares some features with other retinal degenerations known to occur from mutations.

Dry Macular Degeneration

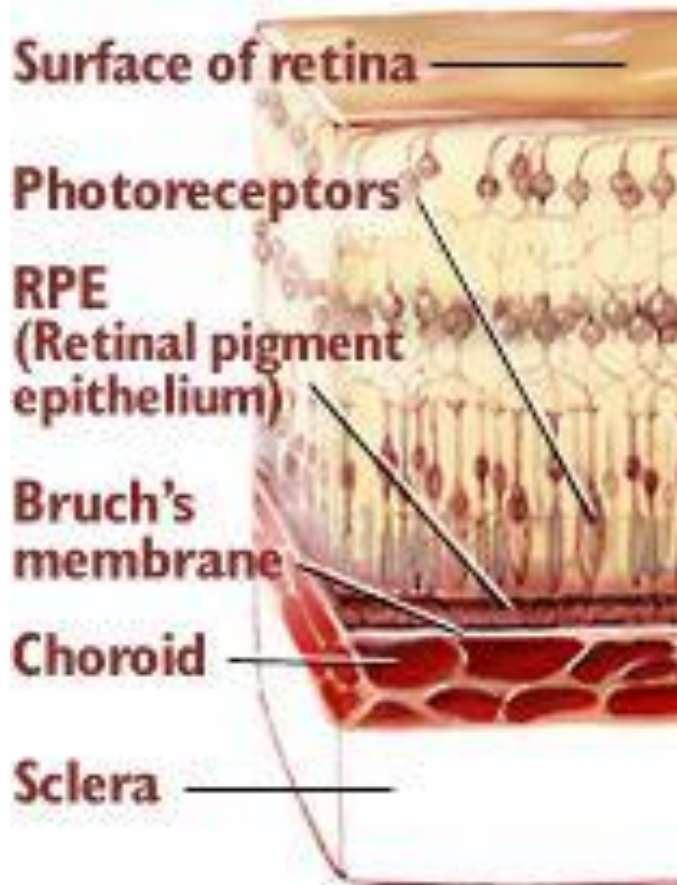
Anatomy of retina and posterior eye



“Dry” macular degeneration

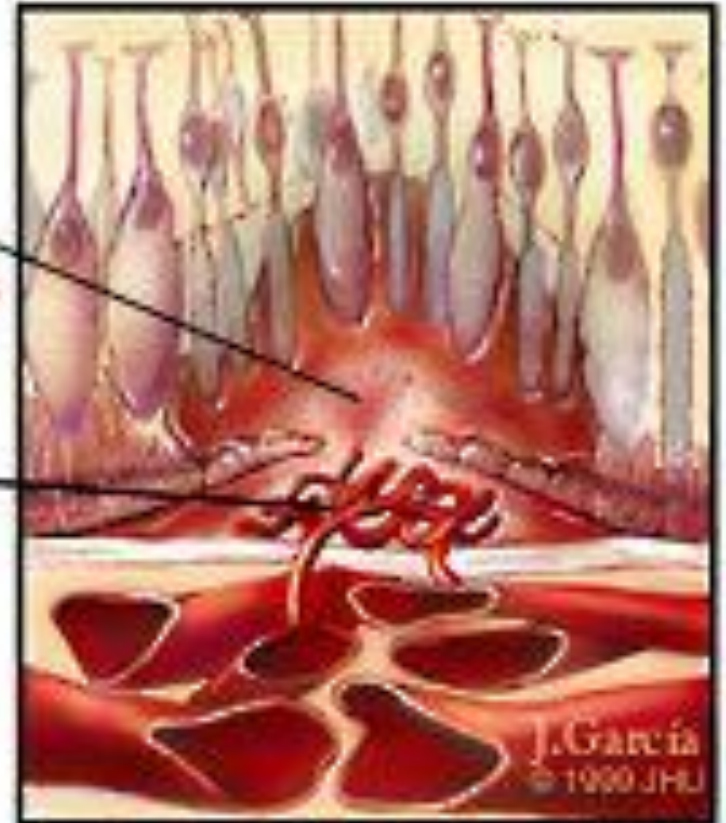
Wet Macular Degeneration

Anatomy of retina and posterior eye



Subretinal hemorrhage

CNV

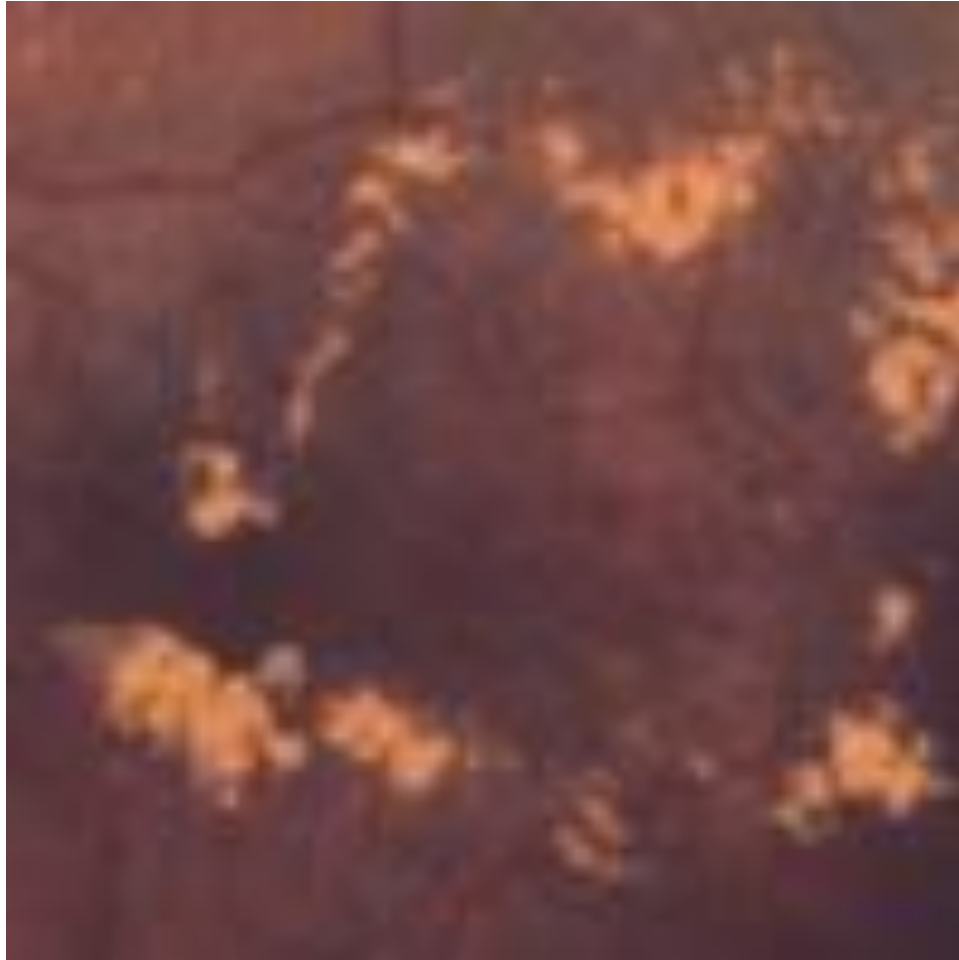

“Wet” macular degeneration

Diabetic Macular Edema

National Eye Institute, National Institutes of Health

www.nei.nih.gov

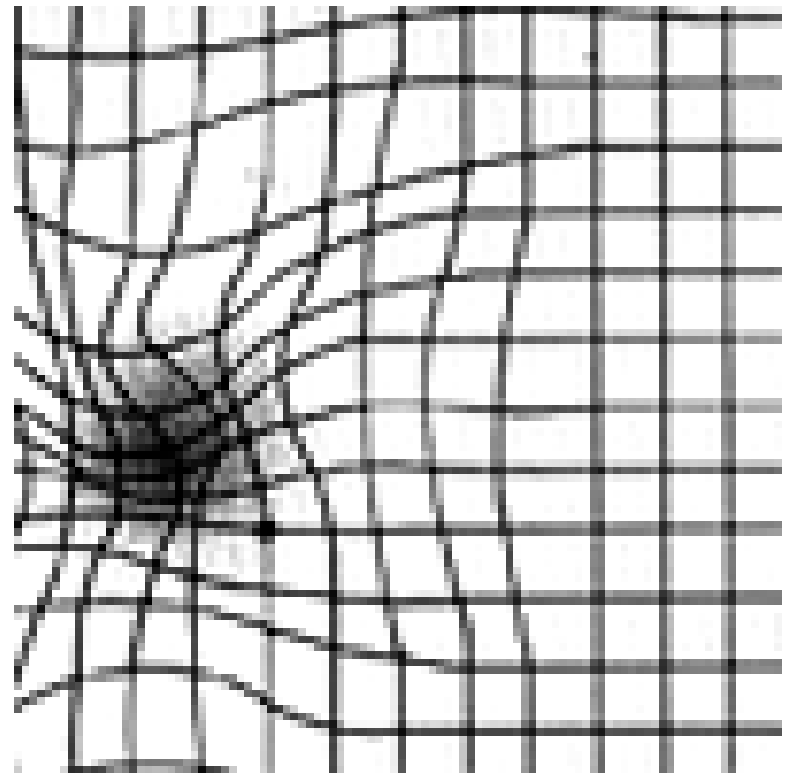
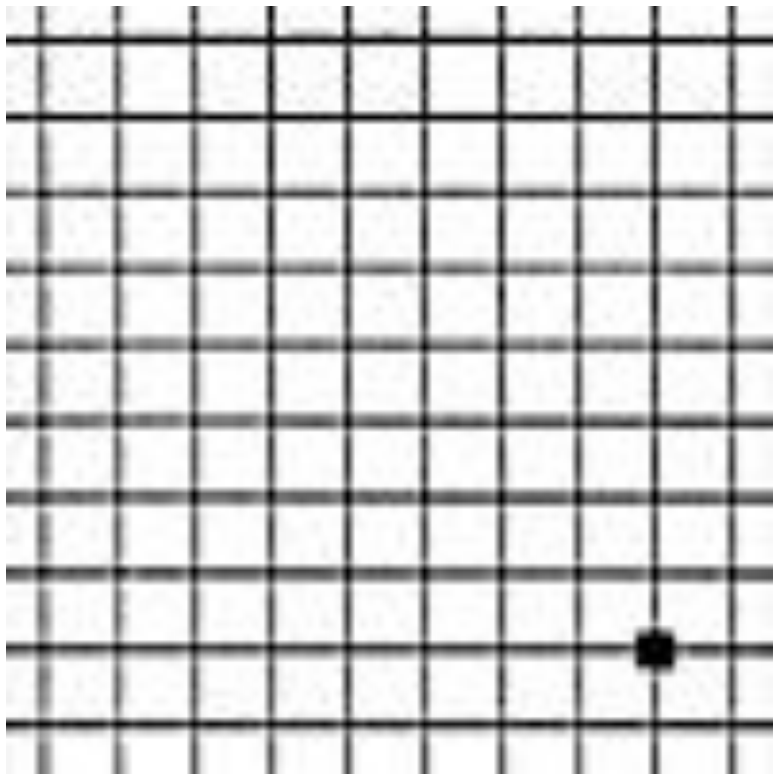


Vision with Macular Degeneration National


Eye Institute, National Institutes of Health

www.nei.nih.gov

Amsler grid as it might appear to someone with age-related macular degeneration.



Age Related Macular Degeneration



- A scenes as it might be viewed by a person with Age - Related Macular Degeneration
- National Eye Institute, National Institutes of Health
- www.nei.nih.gov

Age Related Macular Degeneration



Visión normal



- A scenes as it might be viewed by a person with Macular Degeneration
- National Eye Institute, National Institutes of Health
- www.nei.nih.gov

Color Vision



The Effect of IMT on Vision – The Vision/MT Program

Kimberly Burnham, PhD, IMTC, LMT

INTRODUCTION

"Eyes that see do not grow old." Nicomachus saying

There are more and more people who are improving their vision through the use of hands on therapies from the field of Complementary and Alternative Medicine as well as by shifting diet and nutrition and doing visual exercises.

VISION/MT

Vision/MT, a department of the Connecticut School of Integrative Manual Therapy, synthesizes the skills of many practitioners, including massage therapists, PTs, functional vision experts, and behavioral optometrists. All work towards improving the client's visual function and overall health.

METHODS and TREATMENT

Advanced Strain and Counterstrain for relaxation of eye muscles and blood vessels supplying the eyes to improve circulation. **Neural Tissue Tension** to decompression on the nerve, improve growth and development of the optic nerve and nerves to the eye. **Compression Syndromes and Muscle Energy** to improve circulation, movement and space in and around the eyes. **Recovery Motifities** (Disruptions of Membranes, Bone/Braine, Immune Deficiency Motifity) to increase eye health and integrity. **Postural Reflexes** to stabilize balance, hand-eye coordination and ocular reflexes. **Physical Functional Medicine** to restore normal motifities and physiology. **Biophysiology** to a conscious nutrition to the eyes.


**IMT Symposium
 March, 2007**

RESULTS

Client A: 0.25 and .5 diopter improvement in vision in 1 year.

Client B: "Now for the really exciting news! I saw the optometrist yesterday. Eight months ago I had an extensive eye exam. Since then, my prescription changed .5 diopters and, best of all, my astigmatism is gone—completely—30 years worth. The objective changes are wonderful, but even more so, what it means to me is, my vision is literally not so distorted and I can trust what I see. I realize how happy this ties into my trust issues and the ability to trust what I perceive."

Client C: An 82 year-old client put her recovery this way, "after 15 hours of IMT treatment, my optometrist said my wet macular degeneration had not worsened in the previous year. I find that I can read and drive better. Colors seem brighter."



Keratoconus, Nystagmus and Migraines

"I have keratoconus, a genetic disorder where the cornea becomes weaker than it should be. I also had nystagmus, where the eyes would get twitchy, especially when I was tired. My knowledge of what can be done with visual and eye related problems is both professional (Director of Vision/MT) and personal."

"For a while the nystagmus was only slightly visible when I was very tired and look to the extreme right side. Now it is completely gone."

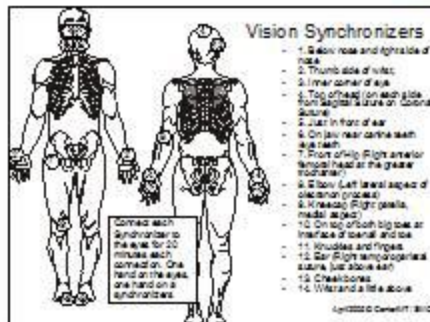
"The keratoconus has stopped degenerating. I have virtually no dysfunctional light sensitivity, which is usually a big problem."

"I have had one migraine headache in the last 5 years, previous to that I had 3-6 severe migraines a year." — Kimberly Burnham

Client A October, 2006 Improved Vision



Vision Synchronizer Hammerk



DISCUSSION and CONCLUSIONS

Strabismus or Lazy Eye

"This is one client's report of her daughter's progress. "I am giving Taylor a little time to adjust to all the changes that may have taken place with the intensive IMT treatment. I'm anxious to see her progress. I'm already noticing that the degree of her eye turn doesn't seem to be as severe. Before her pupil would almost disappear and now that's not the case."

"A few months later, she continues, "Just wanted to let you all know that the appointment with the optometrist went incredible yesterday. The biggest news was that since the intensive, Taylor's degree of eye turn has gone from an 85 degree turn to a 50 degree turn, solely from the Integrative Manual Therapy treatment."

"Then after a few more months, "Taylor's been making some progress. We got her fitted in some glasses that improved the rhythms in her eyes. She's been doing Vision Therapy as well. Her degree of turn has gone from the new 50 degree turn to 45 degrees. Her prescription is also getting better. She was 20/60 and now she's 60/30."

BIBLIOGRAPHY

1. Beckman, M., K. Kawan, et al. (2004). "Tetramelic pressure changes and ocular biometry during Successor (functional posture) in yoga practitioners." *Ophthalmology* 113(5): 1377-52.
2. Collier, S. and C. Hahn, Eds. (2005). *Symptomatic Acute-Onset Ocular Torticollis and cranial nerve dysfunction: a case study of applied kinesiologic cranial evaluation and treatment.* *J Manipulative Physiol Ther.* May;28(4):21-4.
3. Frankel, M. and J. Frankel (2002). "Oculomotor surgery treated with acupuncture." *Altern Ther Health Med* 8(2): 128, 131.
4. Giannantonio, T. and S. Weinstein-Giannantonio (1997). *Integrative manual therapy for the autonomic nervous system and related disorders: utilizing advanced strain and counterstrain techniques.* Berkeley, Calif., North Atlantic Books.
5. Griffin, K. L. (2000). "Facing the pain." *MirrorImage Journal* www.mirrorimage.com
6. Hahn, K. A. (2001). "Natural therapies for ocular disorders, post-traumatic stress, and glaucoma." *Altern Med Rev* 6(2): 141-66.
7. Kwoy, K. and A. I. Taylor (2006). "Cervical lateral dysfunction assessment and manual therapy." *Man Ther* 11(4): 245-53.
8. Weinstein-Giannantonio, S. and T. Giannantonio (2002). *Body wisdom: eight touch for optimal health.* Berkeley, Calif., North Atlantic Books.
9. Winkler, L. (2004). "Advanced Strain Counterstrain." *Massage Therapy Journal* 45 Winter(4): www.massagetherapy.com/journal/vol45_winter4/winter45.html
10. Yamamoto, S. (2006). *Essence to Happiness: The Eyes Have It.* www.siamanatomy.com/essence-to-happiness-2006-page-9-14.pdf

Websites for More Information

1. Center for Integrative Manual Therapy and Diagnostics at www.CenterMT.com
2. For information on the Neuro-Optometric Rehabilitation Association: www.nora.cc
3. For pictures of the eye and different eye conditions: www.xalatan.com/health_professionals_images/illustrations.htm
4. For pictures on how visual dysfunction can affect vision: www.nia.nih.gov/photo/index.htm
5. Main Schneider also has other exercises and information on improving vision at www.self-healing.org

IMT and Vision Reports

Client A

0.25 and .5 diopter improvement in vision in 1 year.

IMT and Vision Reports

Client B: “Now for the really exciting news! I saw the optometrist yesterday. Eight months ago I had an extensive eye exam. Since then, my prescription changed .5 diopters and, best of all, my astigmatism is gone-- completely--30 years worth. The objective changes are wonderful, but even more so, what it means to me is, my vision is literally not so distorted and I can trust what I see. I realize how hugely this ties into my trust issues and the ability to trust what I perceive.”

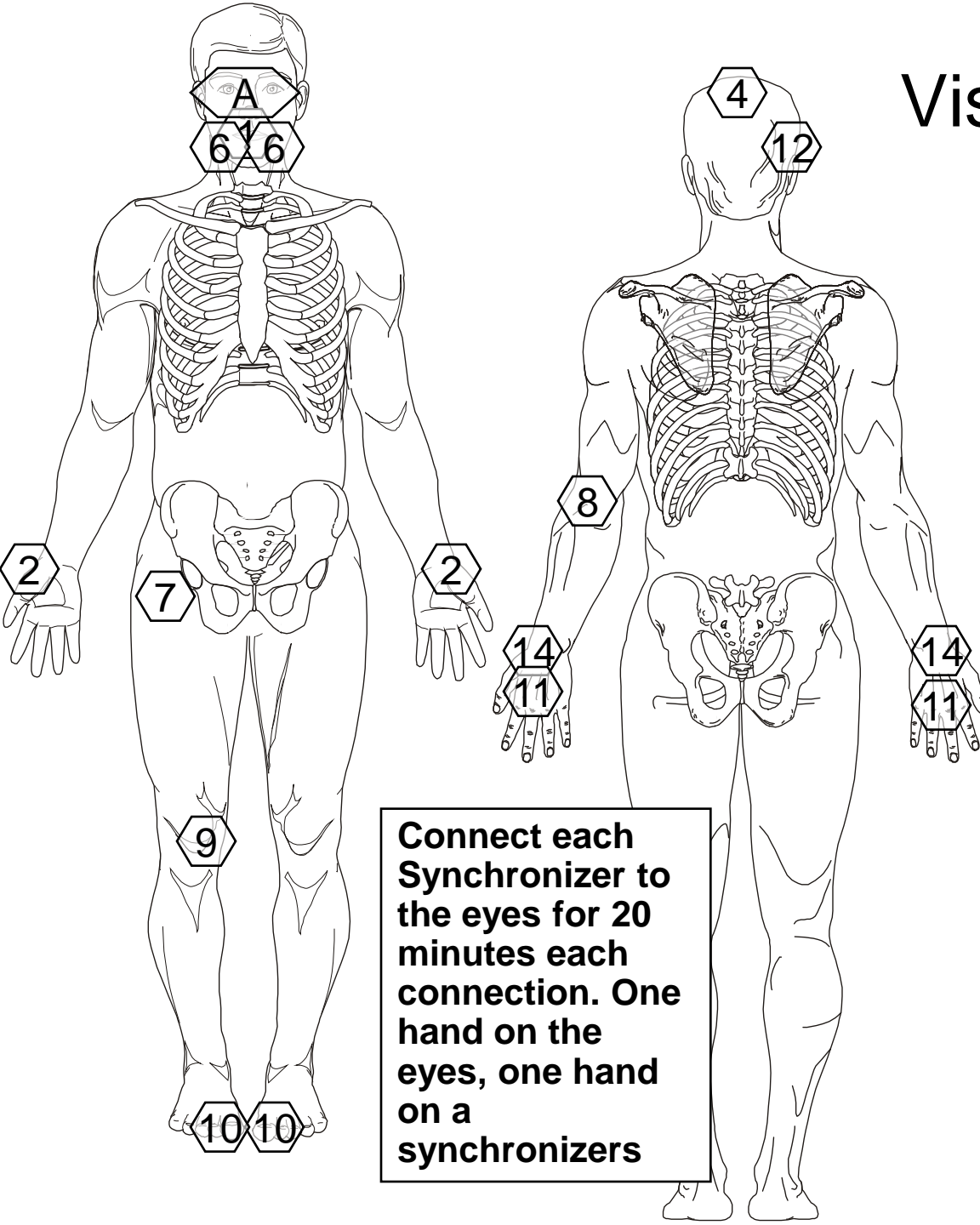
IMT and Vision Reports

Client C: An 82 year-old client put her recovery this way, “after 15 hours of IMT treatment, my ophthalmologist said my wet macular degeneration had not worsened in the previous year. I find that I can read and drive better. Colors seem brighter.”

Science of Wellness Components

Bio Active Component	Health Benefit	Strength of Science	Recommended Amount	Regulatory Status
Polyphenols	Reduced risk of coronary heart disease (58)	Weak/Moderate*		
Lutein/zeaxanthin	Reduce risk of age-related macular degeneration (67)	Weak to moderate	6 mg/d as lutein	Conventional food, dietary supplement
Lycopene	Reduce prostate cancer risk (52-54)	Moderate	1/2 cup/d (30 mg or 10 servings/week)	Conventional food
CLA⁹	Reduce breast cancer (62,63)	Weak	Unknown	Conventional food
Glucosinolates, indoles	Reduce risk of certain types of cancer (39,40,66)	Weak to moderate	>1/2 cup/d	Conventional food

Vision Synchronizers



Connect each Synchronizer to the eyes for 20 minutes each connection. One hand on the eyes, one hand on a synchronizers

1. Below nose and right side of nose
2. Thumb side of wrist,
3. Inner corner of eye
4. Top of head (on each side from Sagittal Suture on Coronal Suture)
5. Just in front of ear
6. On jaw near canine teeth /eye teeth
7. Front of Hip (Right anterior femoral head at the greater trochanter)
8. Elbow (Left lateral aspect of olecranon process)
9. Kneecap (Right patella, medial aspect)
10. On top of both big toes at interface of toenail and toe
11. Knuckles and fingers
12. Ear (Right temporoparietal suture, just above ear)
13. Cheek bones
14. Wrist and a little above

The Observer

<http://www.physics.ohio-state.edu/~wilkins/writing/Assign/topics/bestidea.html>

Light falls into the eye, reflected from the object under observation. But something else, too, must go out from the eye to the things we observe.

